

# Pleomorphic Dermal Sarcoma: a case report

Carmen Déa Ribeiro de Paula <sup>1,\*</sup>, Carolina Bezerra Benévolo Abbud <sup>1</sup>, Luiz Eduardo de Almeida Prado Franceschi <sup>2</sup>, Aridne Souza Costa Campos <sup>1</sup>, Lucas Frizon Greggianin <sup>1</sup>, Isadora Ataíde Caldeira <sup>1</sup>, Vanessa Queiroz Bastos <sup>1</sup>, Juliana Tomaz Esper <sup>1</sup>

<sup>1</sup> Dermatology residency service at the University Hospital of Brasilia, University of Brasília, Brasília, Brazil.

<sup>2</sup> Laboratório Diagnose, Brasília, Brazil.

\* Correspondence: carmendrp@gmail.com.

**Abstract:** This case report brings a 79-year-old man, with a history of melanoma in situ on the extensor part of the left arm, who presented with an ulcerated nodule on the scalp, right parietal region, with rapid and progressive growth for 3 months. The lesion was clinically compatible with squamous cell carcinoma, Merkel carcinoma, amelanotic melanoma and pleomorphic dermal sarcoma. Exeresis was performed and the diagnosis of Pleomorphic Dermal Sarcoma (PDS) was confirmed by histological and immunohistochemical evaluation. Pleomorphic Dermal Sarcoma (PDS), formerly known as malignant fibrous histiocytoma or undifferentiated pleomorphic sarcoma of the skin, is a rare spindle cell mesenchymal tumor that may recur locally or metastasize. Our objective is to present this rare tumor to the reader, discussing the clinical, histological and immunohistochemical presentation, and to highlight the need for further studies on surgical management protocols and the development of guidelines for the standardization of management and safe follow-up of these patients.

**Citation:** Paula CDR, Abbud CBB, Franceschi LEAP, Campos ASC, Greggianin LF, Caldeira IA, Bastos VQ, Esper JT. Pleomorphic Dermal Sarcoma: a case report. Brazilian Journal of Case Reports. 2024 Jan-Mar;04(1):66-71.

Received: 7 December 2022

Accepted: 27 November 2023

Published: 3 December 2023

**Keywords:** Undifferentiated pleomorphic sarcoma; Pleomorphic dermal sarcoma; Atypical fibroxanthoma; Photodamaged skin.



**Copyright:** This work is licensed under a Creative Commons Attribution 4.0 International License (CC BY 4.0).

## 1. Introduction

Pleomorphic Dermal Sarcoma (PDS), formerly known as malignant fibrous histiocytoma or undifferentiated pleomorphic sarcoma of the skin, is a rare spindle cell mesenchymal tumor that may recur locally or metastasize [1, 2, 6, 8, 9, 11]. This term was introduced to reclassify atypical fibroxanthoma-like tumors, as they present additional high-risk characteristics suggestive of greater malignant potential [2, 4-6, 11]. They are tumors formed by histiocytoid, spindle-shaped, epithelioid, and giant multinucleated cells with pleomorphic nuclei. Subcutaneous invasion and necrosis may be present [4]. Immunohistochemistry shows positivity for CD10 and smooth muscle actin (generally nonspecific staining) [3, 4].

The main risk factors described in the development of PDS are ultraviolet radiation, xeroderma pigmentosum and history of organ transplantation [1, 3-5, 10]. Regarding genetic factors, a study that characterized 111 cutaneous sarcomatoid malignancies and their counterparts found that, in PDS, activation of RAS is more frequent, there is frequent *CDKN2A* deletion, there are mutations in *IDH2* and *MAP2K1*, and copy gains in *MET* and *PDGFRA* [10].

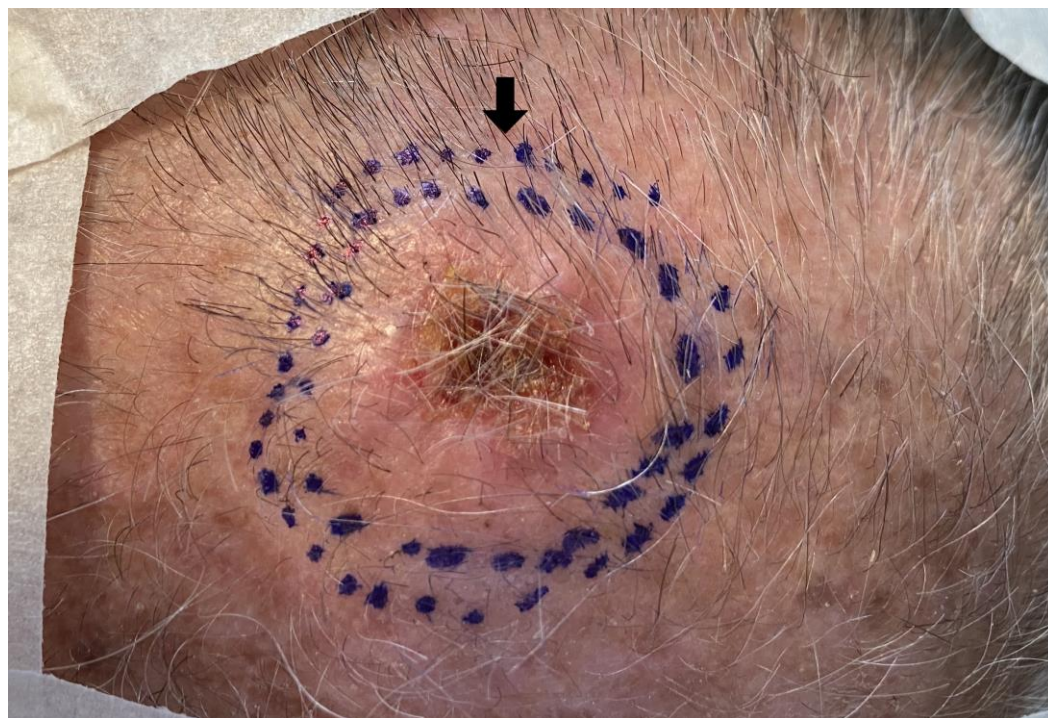
PDS lesions appear on the face and scalp of elderly male patients (mean age of 81 years old) with accentuated photodamage [7]. They are characterized by rapidly growing nodules or infiltrated plaques, often larger than 2 cm, and may progress to ulceration and

bleeding [1, 5, 8, 9]. Some of the possible differential diagnoses are squamous cell carcinoma, Merkel carcinoma, amelanotic melanoma, cutaneous leiomyosarcoma and the AFX [1, 2, 5]. PDS shares similar characteristics with another spindle cell tumor, atypical fibroxanthoma (AFX), which presents a more benign behavior [2, 3, 5, 6]. Therefore, it is essential to distinguish these two neoplasms. Due to its aggressive nature, the gold standard treatment of PDS is surgery and, sometimes, adjuvant radiotherapy in case of metastatic, locally recurrent, or unresectable disease [5, 8, 9, 11].

Our objective is to present this rare tumor to the reader by discussing the clinical, histological and immunohistochemical presentation, and highlight the need for more in-depth studies on surgical management protocols and the development of guidelines for standardizing the management and safe follow-up of these patients.

## 2. Case Report

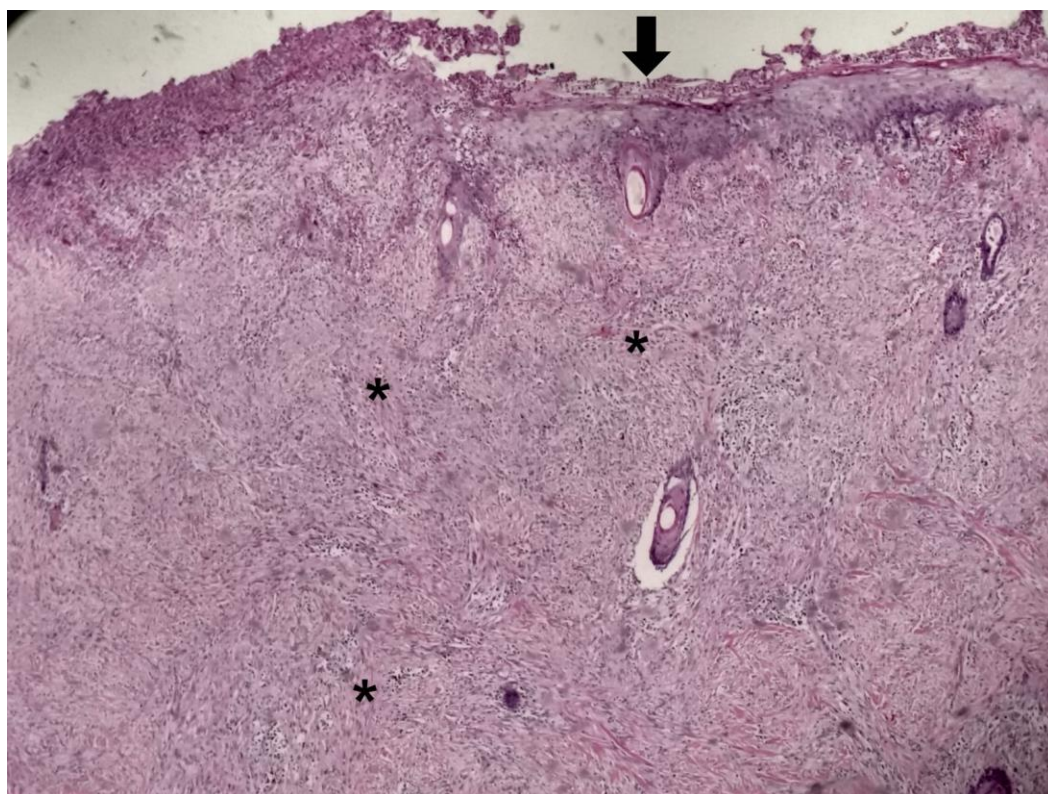
A 79-year-old male patient sought the Dermatology Service of the University Hospital of Brasília due to an infiltrated, erythematous, poorly defined, asymmetrical, ulcerated plaque with a central crust, measuring approximately 2.3 x 1.8 cm in the right parietal region of the scalp (Figure 1). The patient reported rapid and progressive growth in 03 months. He referred long history of sun exposure and previous diagnosis of melanoma in situ in 2000. The melanocytic lesion was located on the extensor part of the left arm, and it was biopsied with small margins. After the diagnostic confirmation of melanoma in situ, new surgery was performed with 5mm margins. The melanocytic lesion was successfully excised, and the patient did not present recurrences or new suspicious melanocytic lesions.



**Figure 1:** Plaque in the scalp (arrow).

On examination, the patient's complaint presented two main differential diagnoses for the group: Merkel carcinoma, due to its history of rapid growth, and squamous cell carcinoma, due to the overlying crust. The lesion was removed by standard margin excision of squamous cell carcinoma and the area reconstructed with skin graft. The resulting sample was sent for histopathological and immunohistochemical evaluation, which showed ulcerated spindle cell proliferation compromising the dermis (Figure 2),

hypodermis and underlying fascia. Twenty-two mitoses were observed in ten high-power fields (22/10 cga).



**Figure 2:** Ulcerated lesion (arrow) and spindle cell proliferation compromising dermis\*.

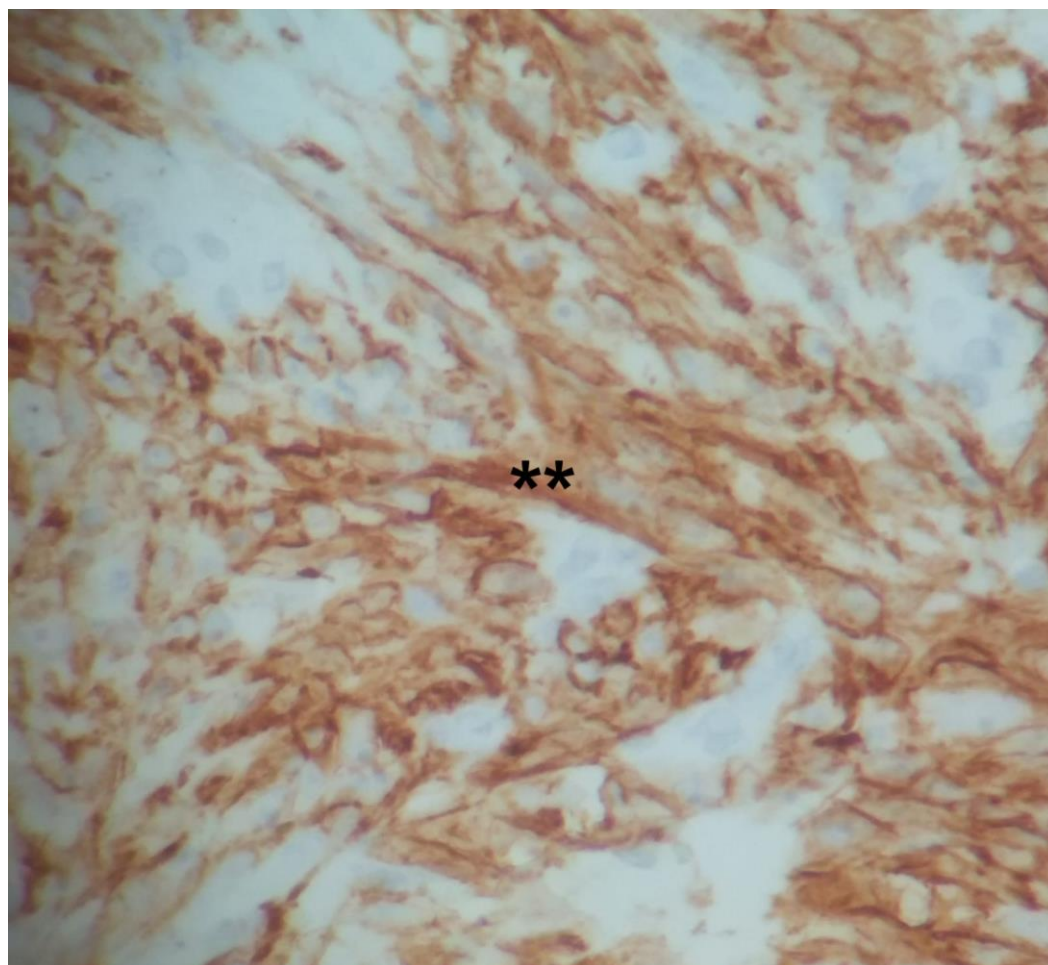
The cells had voluminous, oval, and elongated nuclei, occasionally pleomorphic and the cytoplasm was large, eosinophilic, and elongated. No vascular invasion was identified, however, perineural invasion was observed. There was mild to moderate intra-tumoral and peritumoral lymphoplasmacytic infiltrate. The tumor had an absolute thickness of 5 mm and was excised with free resection margins. Immunohistochemistry was positive for CD10 (clone 56C6) (Figure 3); smooth muscle actin (clone 1A4) (Figure 4) and Ki-67 (cell proliferation marker) (clone MIB-1) in 20% to 30% of the lesion cells. The neoplasm was negative for CD34, S100 and P40, ruling out angiosarcoma, spindle cell melanoma and squamous cell carcinoma. Morphological and immunohistochemical findings were consistent with PDS.

The patient was investigated with cranial and chest CT scans to rule out metastasis, both came without alterations. After 5 months of surgery, the patient returned with local recurrence, confirmed by biopsy, and was again submitted to surgery. The patient remains under follow-up, undergoing screening for local recurrence with annual cranial MRI for the last 2 years, without local recurrence.

### 3. Discussion and conclusion

In the presented case, the anatomopathological examination revealed perineural invasion and deep involvement of the hypodermis and underlying fascia. There was CD10 positivity, which can be found in both PDS and AFX. Diagnostic differentiation with AFX is performed with the presence of one or more of the following characteristics: invasion of deep adipose tissue; tumor necrosis; lymphovascular invasion and/or perineural invasion; local recurrence and metastatic spread [1, 4- 6]. In a series of 32 reported cases of PDS, tumor necrosis was evidenced in 53% of patients; lymphovascular invasion in 26%; perineural invasion in 29%; the presence of positive CD10 in 100% of the cases and a metastatic

rate of 10%.<sup>9</sup> In the presented case, the involvement of the deep subcutaneous and fascia, as well as the perineural invasion, favors the diagnosis of PDS.

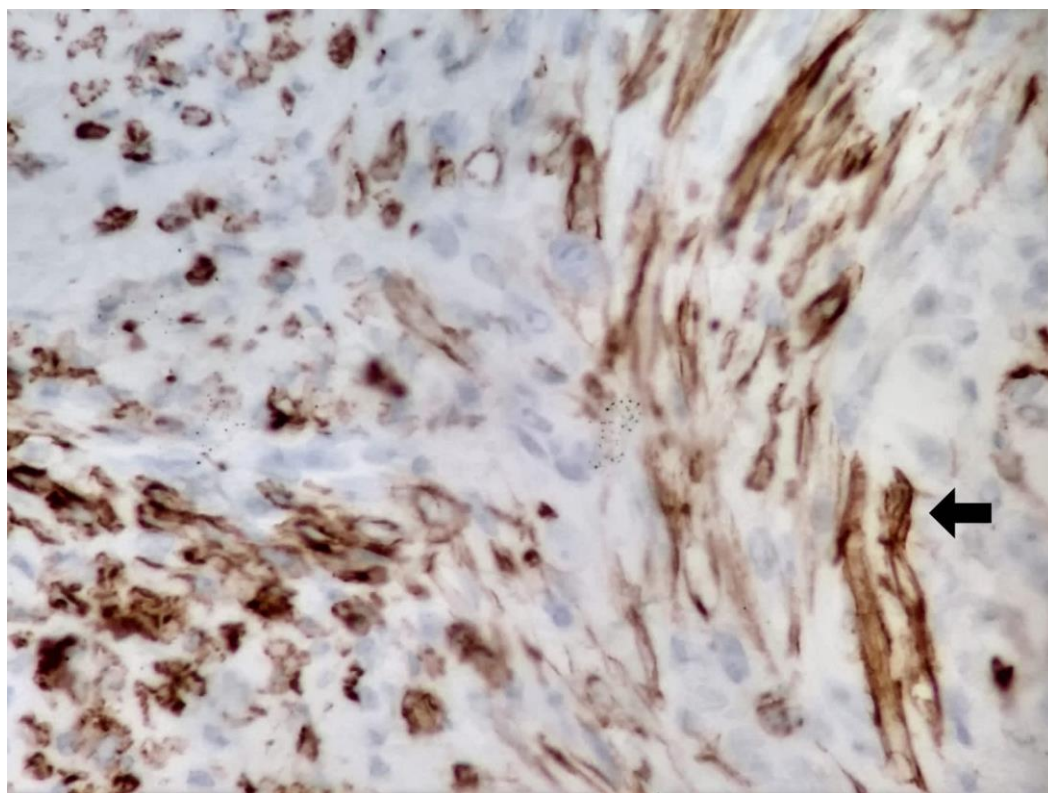


**Figure 3:** Immunohistochemistry positivity for CD10 \*\*.

Lo et al. [7] recently performed a systematic PubMed search on “pleomorphic dermal sarcoma” and found 15 longitudinal studies that provided results specific to PDS. They discovered through meta-analysis and statistical tests that PDS: primarily affects older individuals, predominantly men (82.80%, 95% CI=72.37% to 89.95%, I<sup>2</sup>=62.1%, likelihood-ratio test p=0.011); is largely found on the scalp (68.92%, 95% CI=57.99% to 78.08%, I<sup>2</sup>=54.9%, p=0.019) or the face (13.05%, 95% CI=4.16% to 34.18%, I<sup>2</sup>=88.1%, p<0.0001); recurrence rate was 23.80% (95% CI=17.97% to 30.82%, I<sup>2</sup>=11.5%, p=0.037) and metastasis was 7.14% (95% CI=4.55% to 11.05%, I<sup>2</sup>=0%, 0.261) [7]. Among four of the studies analyzed, local recurrences were due to incomplete removal or inadequate margins [7].

The gold standard treatment for PDS is surgery, using the Mohs micrographic surgery technique or performing wide local excision [5, 8, 11]. Jibbe et al. [11] performed a probability model based on 100 cases extracted from 37 studies with the aim of defining the optimal peripheral margin to eliminate 95% of all tumors. The authors found that 3 cm would be the ideal peripheral margin for the PDS. Another study compared the outcome of 16 patients who underwent surgical treatment, 14 with modified Mohs micrographic surgery (M-MMS) and two with conventional surgery and found that M-MMS led to local disease control in 83% of cases and that 19% of patients evolved with metastasis [11]. After combining the results with those found in literature, an overall metastasis rate of 12% was estimated; and an overall recurrence rate of 35% after conventional

surgery and 17% after M-MMS. It was concluded that M-MMS may be more adequate than conventional excision [11].



**Figure 4:** Immunohistochemistry positivity for smooth muscle actin (arrow).

The evolution and prognosis of PDS are reserved, 20 to 30% of patients have local recurrence, with an average time for recurrence of 10 months, and 10 to 20% have distant metastases to the skin, lymph nodes and/or lungs [2, 4, 6, 9]. The presence of metastatic disease is associated with an increased mortality rate [7, 9, 11]. The present case report draws attention to the importance of including PDS as one of the differential diagnoses in the investigation of skin tumors, specially of the scalp, in elderly patients with pronounced photodamaged. Furthermore, we highlight the need for further studies on the development of management guidelines and standardization of safe follow-up of these patients.

**Funding:** None.

**Research Ethics Committee Approval:** We declare that the patient approved the study by signing an informed consent form and the study followed the ethical guidelines established by the Declaration of Helsinki.

**Acknowledgments:** None.

**Conflicts of Interest:** None.

**Supplementary Materials:** None.

## References

1. Bowe CM, Godhania B, Whittaker M, Walsh S. Pleomorphic dermal sarcoma: a clinical and histological review of 49 cases. *Br J Oral Maxillofac Surg.* 2021;59(4):460-465. doi: 10.1016/j.bjoms.2020.09.007.
2. Devine RL, Cameron A, Holden AM, Basiouni A, Colbert SD. The Pleomorphic Dermal Sarcoma: Its management, follow-up and the need for more guidance. *Adv Oral Maxillofac Surg.* 2021;2:100046. doi: 10.1016/j.adoms.2021.100046.

3. Helbig D, Mauch C, Buettner R, Quaas A. Immunohistochemical expression of melanocytic and myofibroblastic markers and their molecular correlation in atypical fibroxanthomas and pleomorphic dermal sarcomas. *J Cutan Pathol.* 2018;45(12):880-885. doi: 10.1111/cup.13346.
4. Iglesias-Pena N, Martínez-Campayo N, López-Solache L. Relación entre fibroxantoma atípico y sarcoma pleomórfico dérmico: histopatología de ambos y revisión de la literatura. *Actas Dermosifiliogr.* 2021;112(5):392-405. doi: 10.1016/j.ad.2020.11.018.
5. Jibbe A, Worley B, Miller CH, Alam M. Surgical excision margins for fibrohistiocytic tumors, including atypical fibroxanthoma and undifferentiated pleomorphic sarcoma: A probability model based on a systematic review. *J Am Acad Dermatol.* 2021. doi: 10.1016/j.jaad.2021.09.036.
6. Kravvas G, Veitch D, Logan IT, Perrett CM. Metastatic pleomorphic dermal sarcoma: an uncommon skin tumor. *An Bras Dermatol.* 2018;93(2):307-308. doi: 10.1590/abd1806-4841.20187228.
7. Lo ACQ, McDonald S, Wong KY. Case of pleomorphic dermal sarcoma with systematic review of disease characteristics, outcomes and management. *BMJ Case Rep. CP* 2021;14:e244522. doi: 10.1136/bcr-2021-244522.
8. Lonie S, Yau B, Henderson M, Gyorki D, Angel C, Webb A. Management of pleomorphic dermal sarcoma. *ANZ J Surg.* 2020;90(11):2322-2324. doi: 10.1111/ans.15909.
9. Miller K, Goodlad JR, Brenn T. Pleomorphic dermal sarcoma: adverse histologic features predict aggressive behavior and allow distinction from atypical fibroxanthoma. *Am J Surg Pathol.* 2012;36:1317-1326. doi: 10.1097/PAS.0b013e31825359e1.
10. Miller TI, Zoumberos NA, Johnson B, Rhodes DR, Tomlins SA, Chan MP, et al. A genomic survey of sarcomas on sun-exposed skin reveals distinctive candidate drivers and potentially targetable mutations. *Hum Pathol.* 2020;102:60-69. doi: 10.1016/j.humpath.2020.06.003.
11. Ríos-Viñuela E, Serra-Guillén C, Llombart B, Requena C, Nagore E, Traves V, Guillén C, Vázquez D, Sanmartín O. Pleomorphic dermal sarcoma: a retrospective study of 16 cases in a dermatology centre and a review of the literature. *Eur J Dermatol.* 2020;30(5):545-553. doi: 10.1684/ejd.2020.3875.