

# Inguinodynia after inguinal hernioplasty - clinical and surgical management: a literature review

Fernanda Moreira Boaventura 1, Mariana Mussalem Santos 1, Mariana Tafner Perondini 1, Pedro Guimenti Ribeiro de Lima 1, João Kleber de Almeida Gentile 2 \*

<sup>1</sup> Graduation in Medical School of São Paulo City University (FM-UNICID).

<sup>2</sup> Digestive Surgeon. Specialist Titular Member of the Brazilian College of Digestive Surgery (CBCD). Fellow of American College of Surgeons (FACS). Professor of Operative Technique and Surgical Skills of the Faculdade de Medicina da Universidade Cidade de São Paulo (FM-UNICID). São Paulo, SP, Brazil.

\*Corresponding author: João Kleber de Almeida Gentile. Rua Padre Estevão Pernet, 180 - Tatuapé, São Paulo/SP. Zip Code: 03315-000 – São Paulo, SP, Brazil. Phone: +55 (11) 2093-1303. E-mail: joaokleberg@gmail.com.

**Research Ethics Committee Approval (if necessary):** Not applied.

Received on: Jun 12, 2022. Accepted on: Jul 7, 2022. Available online: Jul 14, 2022.

## Abstract

Inguinodynia (chronic inguinal pain) is one of the most feared complications for surgeons after inguinal hernia repair with prosthetic mesh placement. The biopsychosocial impact of this complication can lead to a considerable decrease in patients quality of life. Chronic inguinal pain can appear at varying periods after surgery, for weeks to years after the surgical procedure. The pain is classified as neuropathic and non-neuropathic related to nerve injury and mesh, respectively. The diagnosis and clinical management of this condition is a separate challenge for medical specialists in hernia surgery, requiring a thorough knowledge of inguinal anatomy, advanced surgical knowledge, and literature references on the subject are still limited. In this article we discuss the diagnostic and therapeutic tools as well as the surgical maneuvers for the intervention of inguinodynia.

**Keywords:** Inguinal hernia; Inguinal canal; Chronic pain, Nociceptive pain; Postoperative pain.

## Introduction

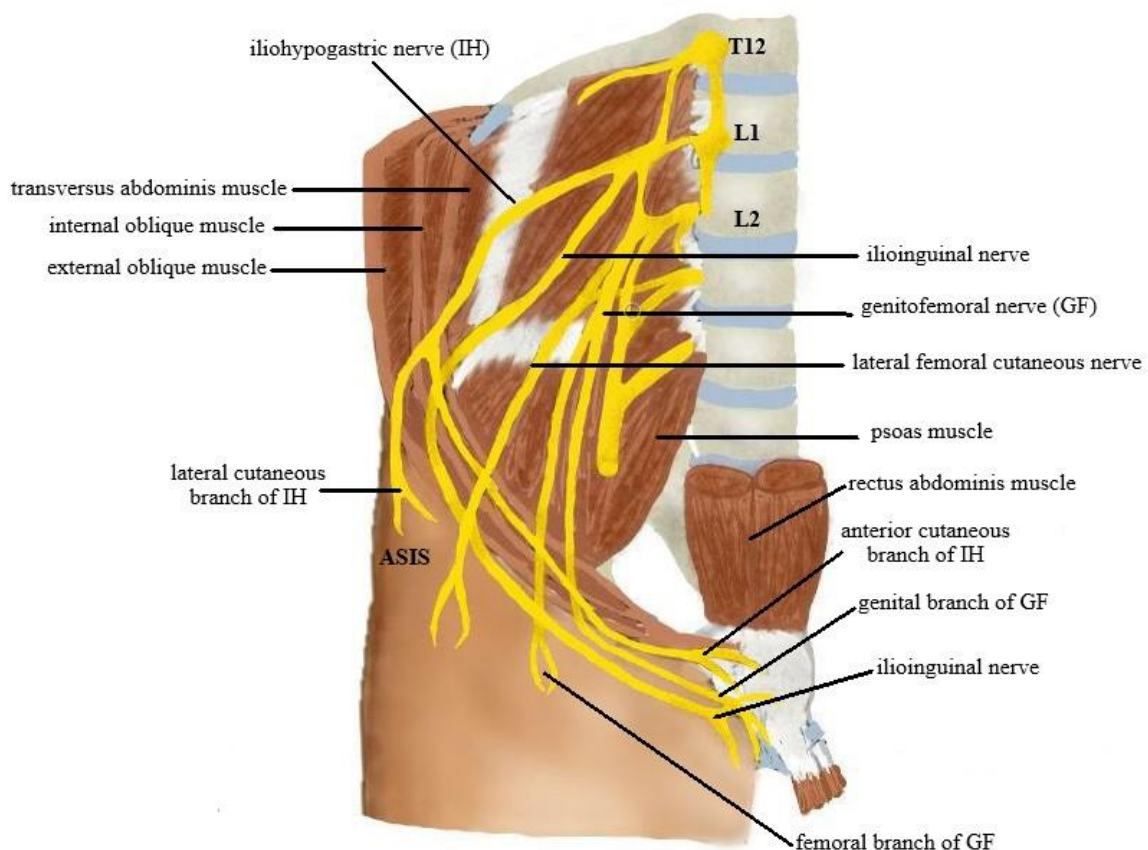
Inguinodynia, also called chronic post-herniorrhaphy pain or chronic postoperative inguinal pain (CPIP), according to the International Asso-

ciation for the Study of Pain (IASP), is pain lasting more than three months after herniorrhaphy. It is defined as groin pain of recent onset, with characteristics different from the preoperative one, of at least moderate

intensity with impact on daily activities, persisting for at least three months after the herniorrhaphy. Although most studies show inguinodynia as a chronic pain lasting at least three months, some authors point out that the healing process resulting from inflammatory tissue reactions after mesh repair may be even more prolonged, so there has been a change in the definition of chronic pain to a duration longer than six months [1-4].

The etiology of inguinodynia is multifactorial and can be classified as neuropathic pain or nociceptive pain.

The former can be characterized by paresthesia (tingling sensation), hypoesthesia (sensation of reduced sensitivity), allodynia (presence of pain during a non-painful stimulus), and hyperalgesia (increased pain sensitivity), usually with worsening of the symptoms on walking and sitting, resulting from a direct lesion of one or more nerves during nerves during herniorrhaphy, with greater occurrence in the iliohypogastric nerves, ilioinguinal and genital branch of the genitofemoral nerve (Figure 1) [1, 2].



**Figure 1.** Representation of the origin and course of the main nerves of the pelvic and inguinal region. Special reinforcement for the iliohypogastric, ilioinguinal and genitofemoral nerves and their branches. Received from the Department of Operative

Technique and Surgical Skills of the Medical School of the City University of São Paulo (FM-UNICID).

Thus, sectioning, trapping, stretching, or compressing the nerve by sutures, staples, meshes, and other fixation instruments interrupts axonal continuity, so in an attempt to restore local innervation, axons regenerate and may become atrophic or form a neuroma, a scar tissue, leading to neuropathic pain. It is also necessary to pay attention that any incision in the skin during open herniorrhaphy damages the branches of the inguinal nerves, therefore, there is a natural risk for neuropathic pain [1, 2].

Noiceptive pain is mediated by tissue injury followed by inflammation without nerve damage. Thus, it is described as a throbbing pain in the groin region and may be related to muscle or ligament spasm, perineural fibrosis, "meshoma" pain (a mass formed by a retractile hernia mesh) and periprosthetic fibrosis, related to wrinkling, migration or folding of the mesh, and the suture or fixation material [2, 4].

Polypropylene, a synthetic mesh material, recurrently used in tension-free techniques, is one of the materials responsible for triggering granulomatous reactions that surround the fibers of the material, allowing an encapsulation of the mesh, which can lead to the formation of fibrosis consequently to pain [1, 4].

The data on the incidence of inguinodynia varies considerably among the studies analyzed, regardless of the surgical technique used. Some studies demonstrate the incidence of chronic postoperative inguinal pain in 10% to 20% of patients, and other studies have reported an incidence of up to 30% [1-10].

Inguinodynia varies in intensity, and may be mild, moderate, or even severe, often making it impossible to perform daily activities. The incidence of moderate or severe inguinodynia, which leads to interference in daily activities, and even at work, is from 0.5 to 6% of patients, and may reach 12% [11-14].

## Methods

In this study, we conducted a literature review as a methodological strategy, searching for articles in the Latin American and Caribbean Health Sciences (LILACS), Scientific Electronic Library Online (SciELO), and National Library of Medicine (PubMed), in which descriptors were chosen and identified according to the Medical Subject Headings (MeSH) and Health Sciences Descriptors (DeCS) lists of descriptors, as follows: inguinal hernia; chronic pain; pain, postoperative. Among the studies, articles published between 2012 and 2022 in English and Portuguese were eligible, not including book chapters

and non-systematic reviews. Initially the articles were selected by title and abstract.

## Literature Review

The risk factors for inguinal hernia recurrence can be classified as perioperative factors and patient and hernia factors. Among the perioperative factors we can mention the learning curve and the surgeon's mental and physical state, the operative time, anesthesia, the use or not of a mesh, the mesh characteristics (type, size, fixation method) and the surgical method (laparoscopic or laparotomy).

Regarding the patient's risk factors, we highlight age (below 40-50 years old), BMI, female gender, smoking, scarring, surgical site infection, and time to return to daily physical activities [2, 9, 15-18].

In the matter of patient age, younger patients report pain and functional impairment 1 year after surgery more frequently than those older than 65 years [8].

The risk for inguinodynia is strongly related to female gender, young age, high preoperative pain intensity, high early postoperative pain intensity, history of chronic pain other than chronic postoperative inguinal pain, operation for recurrent hernia, and open repair technique. The most relevant factor in the development of chronic pain is immediate postoperative pain and therefore should be identified

and appropriately treated, acting as a preventive measure for inguinodynia [1, 4, 5, 11, 19].

According to a clinical trial from Sweden, there seems to be a genetic predisposition for chronic postoperative pain. HLA DRB1 genotyping of 189 patients with and without inguinodynia was performed, and the results showed that patients with chronic pain were carrying DRB1\*04 much more frequently than patients in the pain-free group. Additional typing of the DQB1 gene further strengthened the association; carriers of the DQB1\*03:02 allele along with DRB1\*04 had an increased risk of postsurgical pain compared to non-carriers [2].

## Surgical technique

Inguinal herniorrhaphy techniques are divided into anterior repair, tissue repair, anterior tension-free inguinal hernia repair, preperitoneal repair, and laparoscopic repair. Within these, we observed a higher frequency of inguinodynia in patients undergoing open surgery. This can be explained by the wider incision that directly interferes with the main inguinal sensory nerves.

In laparoendoscopic inguinal hernia repair, the inguinal nerves remain in their natural socket and are separated from the dissection plane by a fascial layer. In open repair, the skin incision always implies nerve damage. In addition, open mesh implantation usually interferes with the ilioinguinal nerve. These nerve injuries occur mainly

due to failure to visualize and protect the nerves, failure to recognize the location of anatomical variations of the nerves, and inadequate dissection. Therefore, it is recommended to identify the nerves via inguinal ultrasound or identify them visually during open herniorrhaphy [1, 2, 9].

Preventive surgical options for inguinodynia include preservation of the nerves with or without their mobilization, prophylactic neurectomy, or pragmatic neurectomy. Identification and preservation of all three inguinal nerves reduces the risk of chronic inguinal postoperative pain. In contrast, general prophylactic neurectomy cannot be recommended in open inguinal hernia repair because it does not reduce the risk of pain and adds sensory loss, which is itself a risk factor for chronic pain. The term "pragmatic neurectomy" was coined for resection of nerves damaged by hernia, scar tissue, surgical trauma, or nerves at risk of damage primarily due to interference with the mesh. The latest guidelines on the management of inguinal hernia set a strong recommendation in favor of pragmatic neurectomy [1, 2, 4].

Chronic postoperative pain is frequently reported after inguinal hernia repair with mesh, from 11.0% to 40.5%, and has a significant impact on quality of life [20]. Men repaired with mesh for an inguinal hernia do not have impaired fertility compared to unrepaired men. Recurrence rates are higher after repairs without a mesh [7]. The European

Hernia Society (EHS) makes grade B recommendations on screen fixation:

- *"When using heavy meshes, traumatic mesh fixation in endoscopic TEP repair should be avoided (with the exception of some cases, such as large direct hernias)."*
- *"Atraumatic screen fixation in Lichtenstein technique and endoscopic TAPP repair can be used without increasing the recurrence rate at 1 year" [13].*

### **Anterior repairs**

Anterior repairs are the most common operative approach for inguinal hernias. Some technical aspects of the surgical procedure are common to all anterior repairs. The surgery is initiated by a transversely oriented linear or curvilinear incision slightly above the inguinal ligament and one digital width below the internal inguinal ring. Dissection is performed through Scarpa's subcutaneous tissues and fascia. The external oblique fascia is incised through the superficial inguinal ring to expose the inguinal canal.

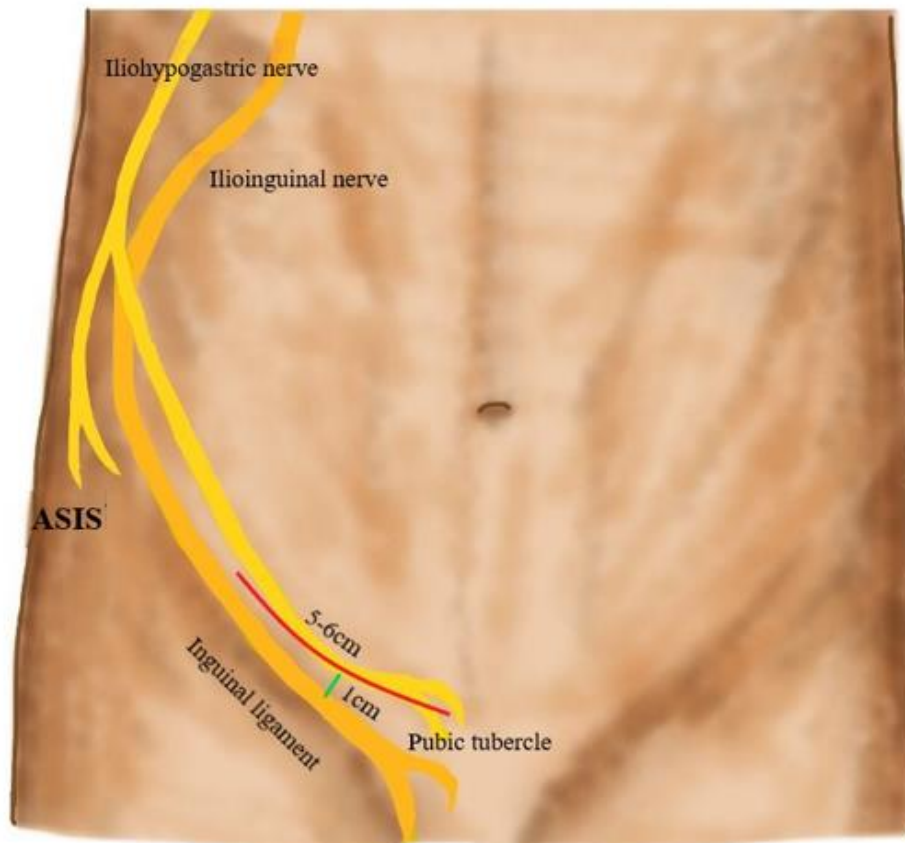
For indirect inguinal hernias, incising the cremaster muscle in a longitudinal direction and dividing it circumferentially near the internal inguinal ring helps expose the indirect hernial sac. The hernial sac is carefully dissected from the adjacent cord structures to the level of the internal inguinal ring. The hernial sac can be mobilized and placed in the preperitoneal space, or the neck of the sac can be ligated at the level of the

internal ring and any excess sac excised [2, 4].

### Tissue repairs

Tension-free repair has become the main method in the surgical treatment of inguinal hernia. With the recognition that tension in the repair is the major cause of recurrence, current practice in hernia treatment employs a synthetic mesh prosthesis to overlap the defect, a concept first popularized by Lichtenstein.

In the Lichtenstein repair (Figure 2), a non-absorbable mesh is placed to protect or reinforce the inguinal canal. A section is made at the distal and lateral margin of the mesh to accommodate the spermatic cord. The mesh is sutured to the aponeurotic tissue that lines the pubic spine medially, continuing superiorly along the transverse abdominis or conjoint tendon.



**Figure 2.** Representation of the incision in the Lichtenstein technique, which is made 1cm above and parallel to the inguinal ligament, beginning at the pubis, extending about 6 cm laterally. ASIS: anterior superior iliac spine. Received from the Department of Operative Technique and Surgical Skills of the Medical School of the City University of São Paulo (FM-UNICID).

The inferolateral margin of the mesh is sutured to the border of the iliopubic tract or shelf of the inguinal ligament to a point lateral to the internal inguinal ring. At this point, the ends created by the opening are sutured together around the spermatic cord [21-24]. Factors in the popularization of the Lichtenstein technique in comparison with the laparoscopic techniques are its ease of execution with fewer serious complications and the possibility of performing the operation under local anesthesia [12].

### Laparoscopic Repair

The laparoscopic approach has the mechanical advantage of placing a large mesh behind the defect, covering the myopectineal hole, and using the natural forces of the abdominal wall to distribute intra-abdominal pressure over a large area to hold the prosthesis in place. Laparoscopic repair is associated with approximately 0.3% risk of visceral or vascular injury.

The most popular techniques include the totally extraperitoneal approach (TEP) and the transabdominal preperitoneal approach (TAPP). The main difference between these two techniques is in the sequence of access gained to the preperitoneal space. In the TEP approach, dissection begins in the preperitoneal space using a dissector balloon. In the TAPP repair, the preperitoneal space is done by access from the peritoneal cavity. Each approach has its benefits. Using the TEP

approach, the preperitoneal dissection is faster, and the potential risk of intraperitoneal visceral injury is minimized. The transabdominal approach enables immediate identification of the anatomy of the inguinal region before extensive dissection of the natural tissue planes. The larger space of the peritoneal cavity approach may facilitate experience with the laparoscopic technique.

Even though the laparoscopic approach is advantageous because it has lower postoperative pain and earlier return to normal activity, chronic postoperative pain is still reported in about 22.5% of patients [17]. Even so, The EndoHernia Society sets a grade A recommendation for laparoscopic hernioplasty to reduce the incidence of chronic postoperative inguinal pain [4].

It is a more technically difficult approach, and intraperitoneal conditions, such as adhesions, may explain the observed delays in TAPP procedures. However, in the case of bilateral hernias, the endoscopic approach seems to be advantageous with respect to surgical time.

They associated TAPP repair with a significantly higher incidence of early postoperative pain compared to TEP, due to the incision of the peritoneum. TAPP is associated with significantly less chronic inguinal pain compared to Lichtenstein repair [23]. There is a lower incidence of chronic postoperative inguinal pain in patients who have undergone TEP compared to

the Lichtenstein technique. In TEP, no repair is applied through muscles and tendons, and there is less chance of regional sensory nerve dissection [1].

TEP repair prevents entry into the peritoneal cavity and peritoneal closure but can be more technically challenging than TAPP repair and has a longer learning curve [21]. The International Endohernia Society (IEHS) updated the guidelines for TEP and TAPP hernia repair in 2015. The IEHS panel concluded:

- *"If the TEP technique is used, non-fixation should be considered in all types of inguinal hernias except large direct hernia defects (MIII, EHS classification)." (Grade A recommendation).*

- *"In case of TAPP repair, non-fixation should be considered in hernia types LI, II and MI, II (EHS classification)" (Grade B recommendation).*

- *"For fixation, fibrin glue should be considered to minimize the risk of acute postoperative postoperative pain" (Grade B recommendation).*

### **Surgical material**

The adequate choice of surgical material is essential to manage and to decrease the risks of chronic pain after inguinal herniorrhaphy. The decision whether or not to use a mesh is also important, since its use is already a factor that decreases the risk of developing inguinodynia [2].

The criteria to be taken into consideration when choosing the ideal material for the patient involve some variables. The mesh should interact well with the tissue, not promote infection, and have minimal shrinkage [30]. Furthermore, the mesh material, pore size, weight and the method of fixation used are extremely important characteristics to be evaluated in order to decrease the risks of chronic pain after inguinal herniorrhaphy.

### **Mesh material**

Almost all the meshes used are made of polypropylene, polyester or polytetrafluoroethylene [30]. Of these three, polypropylene is the most common [22-24]. This material may be related to the incidence of inguinodynia, since the reaction it causes with the tissue makes it rigid and inelastic.

### **Pore size**

The size of the mesh pores is one of the factors to be considered. In this sense, meshes with large pores have better results in preserving elasticity and reducing the inflammatory process [30].

Macroporous polypropylene meshes (> 75 micrometers) are, therefore, more advantageous than microporous ones (< 10 micrometers), precisely because of this more favorable relationship with the inflammatory process and better tissue incorporation. These characteristics of the macroporous mesh promote significantly lower risk of inguinodynia in the patient [1, 30].



### **Mesh weight**

The weight of the mesh is an important factor that can lead or not to chronic postoperative pain. This type of mesh presents less reactive material and thus provokes less inflammatory reactions [12, 22]. Thus, some studies have been able to demonstrate results that favor the use of light mesh, reducing the risk of inguinodynia when compared to heavy mesh. Lightweight meshes demonstrated, besides significant reduction of chronic postoperative pain, less discomfort and foreign body sensation in the long term [1, 2, 3, 12, 16, 22].

A review that analyzed other studies reported lower incidence of inguinodynia by light mesh use, when compared to heavy mesh, in the short term. However, in the long term (3-5 years), there was no difference in pain scales. Of these studies, only one was controversial in concluding that heavy mesh use resulted in lower incidence of inguinodynia [2, 25, 26].

### **Method of fixation**

Several studies have been performed comparing the efficiency of mesh fixation methods in inguinal herniorrhaphy with respect to the incidence of chronic postoperative pain. The methods analyzed were the use of self-adherent mesh, glue, suture fixation, and even penetrating fixation with the use of staples.

The atraumatic meshes, which do not use sutures or penetrating materials, tend to cause less incidence of chronic pain, as they reduce the risk of injuring adjacent nerves [3]. In this sense, some studies have performed direct comparisons between atraumatic methods of fixation and suture fixation in order to assess the incidence of chronic postoperative pain. Some systematic reviews presented data that indicated significant reduction of chronic pain with the use of glue (cyanoacrylate or fibrin glue) when compared with suture fixation [2, 3, 13, 14, 18].

However, comparisons of inguinodynia between these groups, and taking into account the glue and suture fixation method, over time have been performed, which revealed lower incidence of pain with glue use in the short term (1 week and 1 month), whereas in the long term (12 months) the difference between chronic pain was not significant [8, 30]. An analysis of a subgroup of glues, fibrin glue, and suture fixation, demonstrated favorable results for glue use 12 months after inguinal herniorrhaphy [8]. Another study demonstrated that chronic pain with the use of glue in mesh fixation or with the use of suture are comparable, that is, without significant differences [2, 27-29].

Comparison of glue fixation with other materials and methods has also been performed. Fibrin glue fixation was compared with the use of adhesive

mesh in pre-peritoneal transabdominal inguinal hernioplasty, and the results showed no significant differences regarding chronic pain [2]. The use of staples on mesh, as it is a penetrating fixation, is more likely to damage adjacent nerves and therefore result in inguinodynia, thus studies have shown that the use of glue for mesh fixation is preferred over the use of staples [17, 18, 24].

The use of self-adherent mesh in inguinal hernia repair has proven to be quite controversial. Self-adherent meshes were compared with suture fixation in inguinal hernia repairs in one study, and this type of mesh led to better results regarding the development of chronic postoperative pain [14, 16]. On the other hand, since self-adherent meshes have micro-hooks that may induce inflammatory reactions in the tissue by reaching adjacent nerves [12], studies have shown that these meshes failed to demonstrate a lower incidence of inguinodynia or no difference in chronic pain, when compared to the suture fixation method [30, 32], even over time, when an analysis was presented on the use of the ProGrip™ mesh compared to suture fixation, showing that there was also no difference in the incidence of chronic postoperative pain at 1 week, 1 month, and 12 months [8]. It was also analyzed in one study the results of inguinodynia after the use of absorbable and non-absorbable sutures, resulting in no differences [30].

## Treatment

The treatment of patients with inguinodynia is still challenging since there is no universally accepted consensus or guideline for the management of such a condition. Therefore, it is necessary to construct individualized therapeutic plans tailored to clinical features and, in cases of surgical treatment, intraoperative findings (Figure 3) [1, 4].

Thus, conservative treatment is recommended for 3 to 6 months, depending on responses to therapeutic measures. However, there are authors who propose extending treatment to 12 months. The International Association for the Study of Pain (IASP) recommends as first choice for the treatment of neuropathic pain the use of tricyclic antidepressants, serotonin-norepinephrine reuptake inhibitors and voltage-dependent calcium channel blockers. As for the management of nociceptive pain, the use of nonsteroidal anti-inflammatory drugs (NSAIDs) and corticosteroids is recommended, possessing a broad spectrum of efficacy, however, their adverse effects limit their prolonged use [4].

In addition, topical anesthetics such as lidocaine and capsaicin and neurointerventional treatments such as nerve blocks with local anesthetic of the ilioinguinal, iliohypogastric, or genitofemoral nerve are also used in pain management. However, in cases where nerve blocks generate significant analgesia but no long-term relief, the

use of neuroablative techniques such as pulsed radiofrequency, cryoablation, and chemical neurolysis is considered, allowing for more prolonged pain control [4].

Peripheral neuromodulation is also used as an alternative in cases where conventional treatments fail. It is an ultrasound-guided technique of peripheral nerve block, in which, by means of surgical exploration or empirically in incisional scars, the electrodes of the stimulator are placed immediately next to the nerve where the block is desired [27, 29].

As for non-pharmacological therapies, we highlight patient education about the activities that can trigger or exacerbate their pain, guiding the patients to avoid those activities, and physical therapy, considering a multidisciplinary approach to treatment [4, 5, 29].

In cases where conservative therapy is not sufficient for pain control and management, surgical interventions are indicated. Thus, removal of the prosthetic material, i.e., mesh explantation or "meshectomy" should be considered, especially in patients who report nociceptive pain with the presence of "meshoma". On the other hand, mesh explantation involves, besides the risks inherent to surgical reoperation (nerve damage, bleeding, necrosis, etc.), the risk of hernia recurrence. An additional hernioplasty can then be associated to minimize this risk. There are cases in which the

removal of the mesh is enough to stop the chronic pain, although, the removal itself may cause nerve damage when firmly adhered to the structures, resulting in pain persistence. In this scenario, partial removal of the mesh or its removal followed by neurectomy is recommended [1, 4, 20].

Neurectomy is the treatment of choice mainly when neuropathic pain is identified, exhibiting favorable results in the selective or triple technique, open inguinal or retroperitoneal endoscopic routes, however, the latter brings the advantage of minimal invasiveness. Even with the triple neurectomy technique being more aggressive and with a larger area of coverage, it has been the most recommended and has generated greater safety [4].

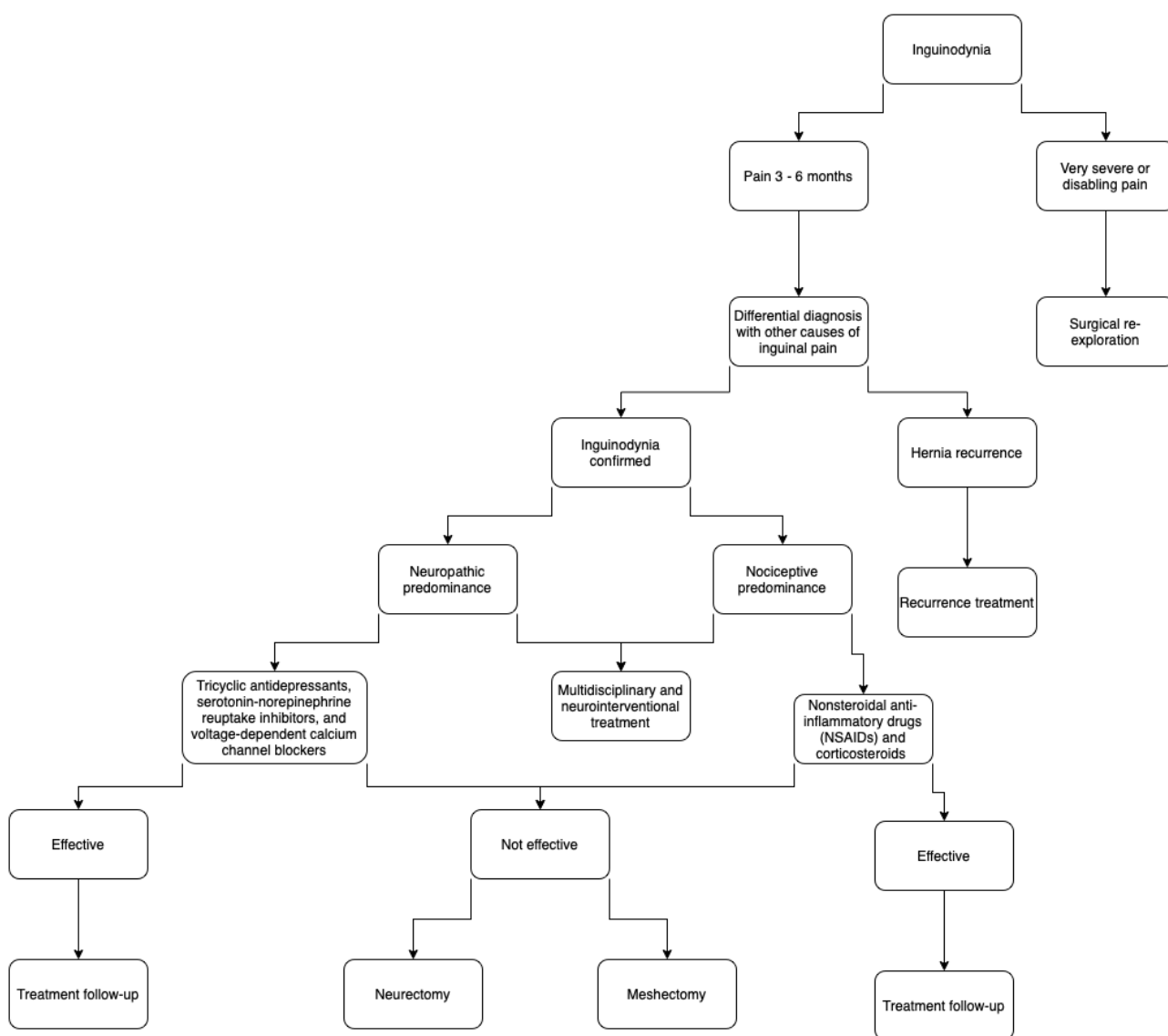
In the case of neurectomy in women, one should pay attention to the preservation of the genital branch of the genitofemoral nerve, responsible for the sensitivity of the labia majora. Moreover, in cases where there is presence of orchialgia or dysejaculation, the triple technique does not bring sufficiently effective results, thus, the removal of the mesh is the best option, since there may be fibrous reaction on the vas deferens and its innervation caused by the prosthetic material. However, in refractory cases, resection of the ductus deferens or orchiectomy may be indicated [4].

## Conclusions

There are still many questions about the management of inguinodynia and associated factors, as well as ways to avoid this complication. Studies show that a good surgical technique can considerably decrease the risk of neurological damage and chronic inguinal pain, but other patient-related

factors may play an important role in its genesis.

The present review showed that there are still no well-established guidelines for the prevention and management of inguinodynia, since its etiology may be multifactorial, requiring an individualized approach for each case.



**Figure 3.** Diagnostic-therapeutic flow for patients with inguinodynia.

## References

- [1] Barbosa CA, Olivieira DC, Melo-Delgado NM, Mafra JGA, Santos RS, Moreira WC. Inguinodinia: revisão sobre fatores predisponentes e manejo. *Rev Col Bras Cir* 47; e20202607. doi: 10.1590/0100-6991e-20202607.
- [2] Reinpold W. Risk factors of chronic pain after inguinal hernia repair: a systematic review. *Innov Surg Sci*. 2017 May 12; 2(2):61-68. doi: 10.1515/iss-2017-0017.
- [3] Sajid MS, Farag S, Singh KK, Miles WF. Systematic review and meta-analysis of published randomized controlled trials comparing the role of self-gripping mesh against suture mesh fixation in patients undergoing open inguinal hernia repair. *Updates Surg*. 2014 Sep; 66(3):189-96.
- [4] Medina Velázquez R, Marchena Gómez J, Luque García MJ. Chronic postoperative inguinal pain: A narrative review. *Cir Esp (Engl Ed)*. 2021 Feb; 99(2):80-88.
- [5] Quevedo Orrego E, Robla Costales J, Rodríguez Aceves C, Diana Martín R, González Álvarez A, Socolovsky M. Neuropathic inguinal pain due to nerve injury after a laparoscopic appendectomy: first pediatric case described in the literature. *Childs Nerv Syst*. 2021 Jun; 37(6):1825-1830. doi: 10.1007/s00381-021-05177-w.
- [6] Lange JF, Meyer VM, Voropai DA, Keus E, Wijsmuller AR, Ploeg RJ, Pierie JP. The role of surgical expertise with regard to chronic postoperative inguinal pain (CPIP) after Lichtenstein correction of inguinal hernia: a systematic review. *Hernia*. 2016 Jun; 20(3):349-56. doi: 10.1007/s10029-016-1483-9.
- [7] Öberg S, Andresen K, Klausen TW, Rosenberg J. Chronic pain after mesh versus nonmesh repair of inguinal hernias: A systematic review and a network meta-analysis of randomized controlled trials. *Surgery*. 2018; 163(5):1151-1159. doi: 10.1016/j.surg.2017.12.017.
- [8] van Steensel S, van Vugt LK, Al Omar AK, Mommers EHH, Breukink SO, Stassen LPS, Winkens B, Bouvy ND. Meta-analysis of postoperative pain using non-sutured or sutured single-layer open mesh repair for inguinal hernia. *BJS Open*. 2019; 3(3):260-273. doi: 10.1002/bjs5.50139.
- [9] Olsson A, Sandblom G, Franneby U, Sondén A, Gunnarsson U, Dahlstrand U. Do postoperative complications correlate to chronic pain following inguinal hernia repair? A prospective cohort study from the Swedish Hernia Register. *Hernia*. 2021; 11. doi: 10.1007/s10029-021-02545-y.

- [10] Charalambous MP, Charalambous CP. Incidence of chronic groin pain following open mesh inguinal hernia repair, and effect of elective division of the ilioinguinal nerve: meta-analysis of randomized controlled trials. *Hernia*. 2018; 22(3):401-409. doi: 10.1007/s10029-018-1753-9.
- [11] Joshi GP, Rawal N, Kehlet H; PROSPECT collaboration, Bonnet F, Camu F, Fischer HB, Neugebauer EA, Schug SA, Simanski CJ. Evidence-based management of postoperative pain in adults undergoing open inguinal hernia surgery. *Br J Surg*. 2012; 99(2):168-85. doi: 10.1002/bjs.7660.
- [12] Molegraaf M, Kaufmann R, Lange J. Comparison of self-gripping mesh and sutured mesh in open inguinal hernia repair: A meta-analysis of long-term results. *Surgery*. 2018; 163(2):351-360. doi: 10.1016/j.surg.2017.08.003.
- [13] Gentile JKA, Franciss MY, Brasil HR, Roll S. Uso do n-butil cianoacrilato em cirurgias da parede abdominal. Revisão de literatura. *Rev Bras Clin Med*. 2016 14(4): 237-238.
- [14] Cunningham HB, Weis JJ, Taveras LR, Huerta S. Mesh migration following abdominal hernia repair: a comprehensive review. *Hernia*. 2019; 23(2):235-243. doi: 10.1007/s10029-019-01898-9.
- [15] Rönkä K, Vironen J, Kössi J, Hulmi T, Silvasti S, Hakala T, Ilves I, Song I, Hertsi M, Juvonen P, Paajanen H. Randomized multicenter trial comparing glue fixation, self-gripping mesh, and suture fixation of mesh in Lichtenstein hernia repair (FinnMesh Study). *Ann Surg*. 2015 Nov; 262(5):714-9. doi: 10.1097/SLA.0000000000001458.
- [16] Ladwa N, Sajid MS, Sains P, Baig MK. Suture mesh fixation versus glue mesh fixation in open inguinal hernia repair: a systematic review and meta-analysis. *Int J Surg*. 2013; 11(2):128-35. doi: 10.1016/j.ijisu.2012.12.013.
- [17] Kaul A, Hutfless S, Le H, Hamed SA, Tymitz K, Nguyen H, Marohn MR. Staple versus fibrin glue fixation in laparoscopic total extraperitoneal repair of inguinal hernia: a systematic review and meta-analysis. *Surg Endosc*. 2012; 26(5):1269-78. doi: 10.1007/s00464-011-2025-2.
- [18] Colvin HS, Rao A, Cavali M, Campanelli G, Amin AI. Glue versus suture fixation of mesh during open repair of inguinal hernias: a systematic review and meta-analysis. *World J Surg*. 2013; 37(10):2282-92.
- [19] Köckerling F, Schug-Pass C. Early Surgical intervention following Inguinal Hernia repair with severe postoperative pain. *Front Surg*. 2017; 30(4):67. doi: 10.3389/fsurg.2017.00067.

- [20] Narita M, Munekage F, Yamaoka R, Ikai I. Mesh shrinkage is the potential pathogenesis of chronic somatic pain following transabdominal preperitoneal repair: Report of two cases. *Asian J Endosc Surg.* 2021; 14(4):798-802. doi: 10.1111/ases.12935.
- [21] Eltair M, Hajibandeh S, Hajibandeh S, Balakrishnan S, Alyamani A, Radoi D, Goh YL, Hanif M, Kumar Y, Mobarak D. Meta-analysis of laparoscopic groin hernia repair with or without mesh fixation. *Int J Surg.* 2019; 71:190-199. doi: 10.1016/j.ijssu.2019.10.004.
- [22] Sajid MS, Kalra L, Parampalli U, Sains PS, Baig MK. A systematic review and meta-analysis evaluating the effectiveness of lightweight mesh against heavyweight mesh in influencing the incidence of chronic groin pain following laparoscopic inguinal hernia repair. *Am J Surg.* 2013; 205(6):726-36. doi: 10.1016/j.amjsurg.2012.07.046
- [23] Scheuermann U, Niebisch S, Lyros O, Jansen-Winkel B, Gockel I. Transabdominal Preperitoneal (TAPP) versus Lichtenstein operation for primary inguinal hernia repair - A systematic review and meta-analysis of randomized controlled trials. *BMC Surg.* 2017; 17(1):55. doi: 10.1186/s12893-017-0253-7.
- [24] Habib Bedwani NAR, Kelada M, Smart N, Szydlo R, Patten DK, Bhargava A. Glue versus mechanical mesh fixation in laparoscopic inguinal hernia repair: meta-analysis and trial sequential analysis of randomized clinical trials. *Br J Surg.* 2021; 108(1):14-23. doi: 10.1093/bjs/znaa002.
- [25] Werner MU, Bischoff JM, Rathmell JP, Kehlet H. Pulsed radiofrequency in the treatment of persistent pain after inguinal herniotomy: a systematic review. *Reg Anesth Pain Med.* 2012; 37(3):340-3.
- [26] Choudhary J, Mishra AK, Jadhav R. Transversalis fascia plane block for the treatment of chronic postherniorrhaphy inguinal pain: a case report. *A A Pract.* 2018; 11(3):57-59.
- [27] Elahi F, Reddy C, Ho D. Ultrasound guided peripheral nerve stimulation implant for management of intractable pain after inguinal herniorrhaphy. *Pain Physician.* 2015; 18(1):E31-8.
- [28] Thapa D, Ahuja V, Verma P, Das C. Successful management of a refractory case of postoperative herniorrhaphy pain with extended duration pulsed radiofrequency. *Saudi J Anaesth.* 2016; 10(1):107-9.
- [29] Bjurstrom MF, Nicol AL, Amid PK, Chen DC. Pain control following inguinal herniorrhaphy: current

perspectives. *J Pain Res.* 2014; 7:277-90. doi: 10.2147/JPR.S47005.

[30] Gentile JKA, Rampazzo Neto A, Teixeira TR, Birindelli JPA, Bassi MA. Estudo das telas cirúrgicas de polipropileno/poliglicaprone-25 e polipropileno monofilamentar no reparo de hérnias inguinais. *Rev Soc Bras Clin Med.* 2016; 14(4): 195-198.

[31] Werner MU. Management of persistent postsurgical inguinal pain. *Langenbecks Arch Surg.* 2014; 399(5):559-69. doi: 10.1007/s00423-014-1211-9.

[32] Ashrafi D, Siddaiah-Subramanya M, Memon B, Memon MA. Causes of recurrences after open inguinal herniorrhaphy. *Hernia.* 2019; 23(4):637-645. doi: 10.1007/s10029-018-1868-z.

[33] Bullen NL, Massey LH, Antoniou SA, Smart NJ, Fortelny RH. Open versus laparoscopic mesh repair of primary unilateral uncomplicated inguinal hernia: a systematic review with meta-analysis and trial sequential analysis. *Hernia.* 2019; 23(3):461-472. doi: 10.1007/s10029-019-01989-7.

[34] Sun P, Cheng X, Deng S, Hu Q, Sun Y, Zheng Q. Mesh fixation with glue versus suture for chronic pain and recurrence in Lichtenstein inguinal hernioplasty. *Cochrane Database Syst*

*Rev.* 2017; 2(2):CD010814. doi: 10.1002/14651858.CD010814.pub2.

[35] Furtado M, Claus CMP, Cavazzola LT, Malcher F, Bakonyi-Neto A, Saad-Hossne R. Sistematização do reparo da hérnia inguinal laparoscópica (TAPP) baseada em um novo conceito anatômico: Y invertido e cinco triângulos. *Arq Bras Cir Dig.* 2019; 32(1):e1426. doi: /10.1590/0102-672020180001e1426.

**Conflict of interest:** The author declares no conflicts of interest.

**Acknowledgements:** None.

**Funding:** None.

**How to cite this article:** Boaventura FM, Santos MM, Perondini MT, de Lima PGR, Gentile JKA. Inguinodynia after inguinal hernioplasty - clinical and surgical management: a literature review. *Brazilian Journal of Case Reports.* 2022 Jul-Sep;02(3):90-105.