

A case of facial vein rupture induced by coughing

Hiroshi Hyakusoku ^{1,*}, Shun Furukawa ¹, Jun Aoyama ¹, Meijin Nakayama ¹

¹ Department of Otorhinolaryngology, Yokosuka Kyosai Hospital, Yokosuka, Japan.

* Correspondence: hhyaku@yokohama-cu.ac.jp.

Abstract: Peritonsillar abscess, deep neck infection, epiglottitis, laryngeal edema, and upper airway foreign bodies are frequently encountered emergencies in otolaryngology wards. In contrast, spontaneous vascular rupture in the neck is rare. A 57-year-old man visited our hospital with left neck pain and sudden onset of submandibular neck swelling after coughing. Contrast-enhanced computed tomography revealed a poorly enhanced mass lesion located at the left upper neck. The most prominent swelling was observed around the facial vein. Exploration of the left mass lesion under general anesthesia was performed. A perforation and gusher were found at the branch of the left common facial vein. The perforation was ligated on both the central and peripheral sides. The rupture of the facial vein was presumed to be idiopathic, possibly caused by coughing. No evidence suggestive of vasculitis syndrome, hereditary predisposition, or symptoms indicating vascular fragility were found. We report the first case report of facial vein rupture possibly induced by coughing with massive swelling on the neck and oral floor. To prevent potential complications, such as airway stenosis due to neck swelling and the risk of hemorrhagic shock, it was necessary to promptly perform imaging diagnostics and surgical intervention to achieve hemostasis and remove the hematoma.

Citation: Hyakusoku H, Furukawa S, Aoyama J, Nakayama M. A case of facial vein rupture induced by coughing. *Brazilian Journal of Case Reports*. 2025 Jan-Dec;05(1):bjcr6.

<https://doi.org/10.52600/2763-583X.bjcr.2025.5.1.bjcr6>

Received: 4 June 2024

Accepted: 25 June 2024

Published: 29 June 2024

Keywords: Coughing up; Idiopathic facial vein rupture; Vascular fragility.



Copyright: This work is licensed under a Creative Commons Attribution 4.0 International License (CC BY 4.0).

1. Introduction

Peritonsillar abscess, deep neck infection, epiglottitis, laryngeal edema, and upper airway foreign bodies are frequently encountered emergencies in otolaryngology wards [1]. Without early intervention, these conditions could lead to an airway emergency, necessitating the establishment of an emergency airway. Spontaneous vascular rupture is rare, with most reported cases occurring after catheter treatment, radiation therapy, surgical treatment, or malignant tumor infiltration [2-5]. Furthermore, most reports of spontaneous venous rupture have been from within the abdominal cavity, such as the iliac vein.[6] As far as we have researched, there have been no reports of spontaneous venous rupture in the neck by coughing. Herein, we report a rare case of facial vein rupture possibly induced by coughing, which required emergency ligation.

2. Case Report

The informed consent was obtained on paper from the patient. A 57-year-old man visited our hospital with left neck pain and sudden onset of submandibular neck swelling after coughing. He had been taking amlodipine and febuxostat for hypertension. He also had gout and kidney stones. At the initial visit, his blood pressure was 188/81 mmHg and heart rate were 104 beats/min. The blood tests were shown in Table 1.

The oral floor and tongue were swollen predominantly to the left from the midline due to hematoma. Hematoma-like bruising was also observed in the left larynx, but

airway obstruction was not observed (Figure 1A). Contrast-enhanced computed tomography (CT) revealed a poorly enhanced mass lesion located at the upper left neck. The most prominent swelling was observed around the facial vein, which suggested potential occurrence of breakthrough bleeding (Figure 1B and 1C).

Table 1. Results of blood tests.

	Initial	Postoperative
WBC (/μL)	6800	
Hb (g/dL)	15.2	
PT-INR	0.84	
APTT (sec)	28.2	
blood sugar (mg/dL)	131	
HbA1c (%)	5.2	
AST (U/L)	30	
ALT (U/L)	18	
BUN (mg/dL)	18	
Creatinine (mg/dL)	0.91	
CRP (mg/dL)	0.08	
HBs Ag (IU/mL)	negative	
HCV Ab (C.O.I)	negative	
TPLA	negative	
RPR latex agglutination (R.U.)	negative	
HIV Ab (C.O.I)	negative	
Antinuclear Ab		negative
Anti-cardiolipin IgG Ab (U/mL)		negative
Anti-ds-DNA IgG Ab (IU/mL)		negative
Anti-Sm Ab		negative
PR3-ANCA (U/mL)		negative
MPO-ANCA (U/mL)		negative
C1- inhibitor (%)		> 200
C3 (mg/mL)		159.0
C4 (mg/mL)		41.4

Legend. Antibody, Ab; Antigen, Ag; Alanine aminotransferase, ALT; Aspartate aminotransferase, AST; Activated partial thromboplastin time, APTT; Blood urea nitrogen, BUN; C-reactive protein, CRP; Double stranded-deoxyribonucleic acid, ds-DNA; Hemoglobin, Hb; Hepatitis B surface, HBs; Hepatitis C virus, HCV; Human immunodeficiency virus, HIV; Myeloperoxidase-anti-neutrophil cytoplasmic antibody, MPO-ANCA; Proteinase-3-anti-neutrophil cytoplasmic antibody, PR3-ANCA; Prothrombin time-international normalized ratio, PT-INR; Rapid plasma regain, RPR; Treponema pallidum latex agglutination, TPLA; White blood cells, WBC.

Exploration of the left mass lesion under general anesthesia was performed (Figure 2A). After incision of skin and platysma muscle, massive hematoma was observed. After identifying the left jugular vein (JV) and the left common facial vein (CFV), a bubble at the anastomosis between the two veins was found (Figure 2B). A vascular clip was placed at the anastomosis to prevent air embolism, and a perforation and gusher were found at the branch of the left CFV (Figure 2C). The central and peripheral sides of the perforation were ligated. No varicose veins were observed. Hematoma was further removed from the neck by manually compressing the oral floor. To avoid further bleeding, the hematoma was removed as much as possible. Tracheal intubation was continued overnight at the

intensive care unit. We administered sulbactam/ampicillin because of inflammation that was observed in blood tests performed after the operation. The transition of White blood cells, Hemoglobin, and C-reactive protein levels was shown in Figure 3.

Nutrition was administered through a gastric tube due to difficulty with oral intake caused by tongue swelling. Oral intake began on the 8th day post-operation.

Figure 1. A. Fiber-optic nasopharyngolaryngoscope. Submucosal hemorrhage in the left larynx was observed (arrow), whereas no airway stenoses or mucosal swelling were observed in the larynx. Contrast-enhanced CT (B. axial, c. coronal). Left neck swelling around the left facial vein was observed. Arrow: jugular vein. Arrowhead: common facial vein.

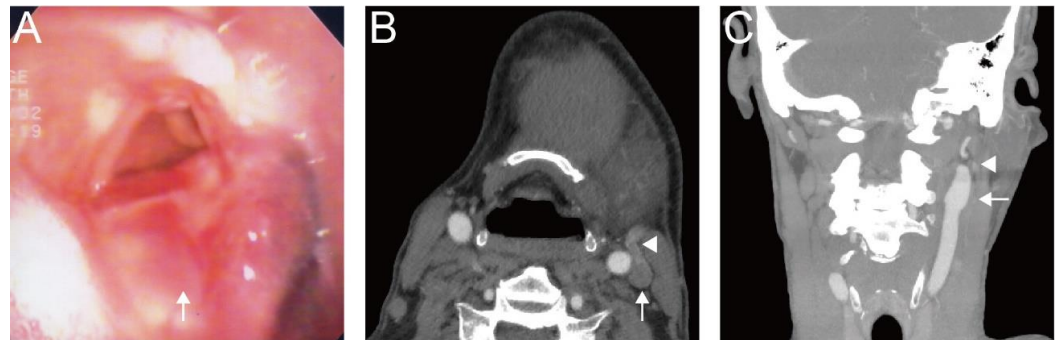
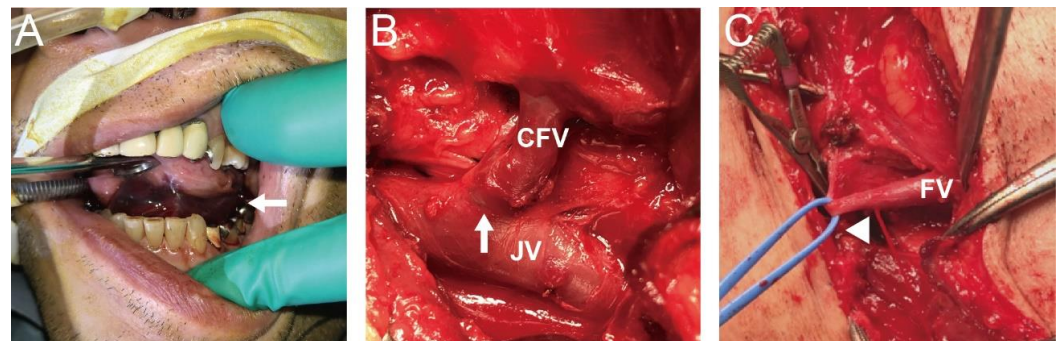


Figure 2. A. Intraoral findings. Submucosal hematoma in the oral floor was observed and oral floor showed swelling and bleeding (arrow). B. A bubble (arrow) was observed in the vessel at the anastomoses between the jugular vein (JV) and the common facial vein (CFV). C. Perforation (arrowhead) was observed in the facial vein (FV) branching from the CFV.



To further investigate the cause of the venous abnormalities, additional blood tests and CT angiography were performed. The blood tests were all negative for antibodies without hypocomplementemia (Table 1). Vasculitis from the neck to the pelvis, aneurysms, and varicose veins were not observed (Figure 4). He declined to take skin biopsy and genetic tests for the differential diagnosis of Ehlers-Danlos syndrome.

3. Discussion

We reported a case of facial vein rupture possibly induced by coughing. Massive swelling on the neck and oral floor were the main symptoms. This is the first case report of venous rupture possibly related to vascular fragility. Vasculitis syndrome; secondary vasculitis, such as connective tissue disorders, infection, and neoplasm; and Ehlers-Danlos syndrome due to vascular fragility and hematologic diseases can cause venous rupture (Table 2) [7]. Vasculitis syndrome is categorized by blood vessel size: Takayasu's arteritis and giant cell arteritis induce inflammation in large vessels, whereas polyarteritis nodosa and Kawasaki disease affect medium-sized vessels. It is important to note that diseases

involving large and medium-sized vessels are arteritis, not phlebitis. In the range of small vessel-related conditions, all vasculitides were excluded in this case due to the absence of viral infection, cancer, or any associated symptoms or dysfunctions, along with negative results in the tested antibodies.

Figure 3. The transition of WBC, Hb, and CRP levels. White blood cells, WBC; Hemoglobin, Hb; C-reactive protein, CRP.

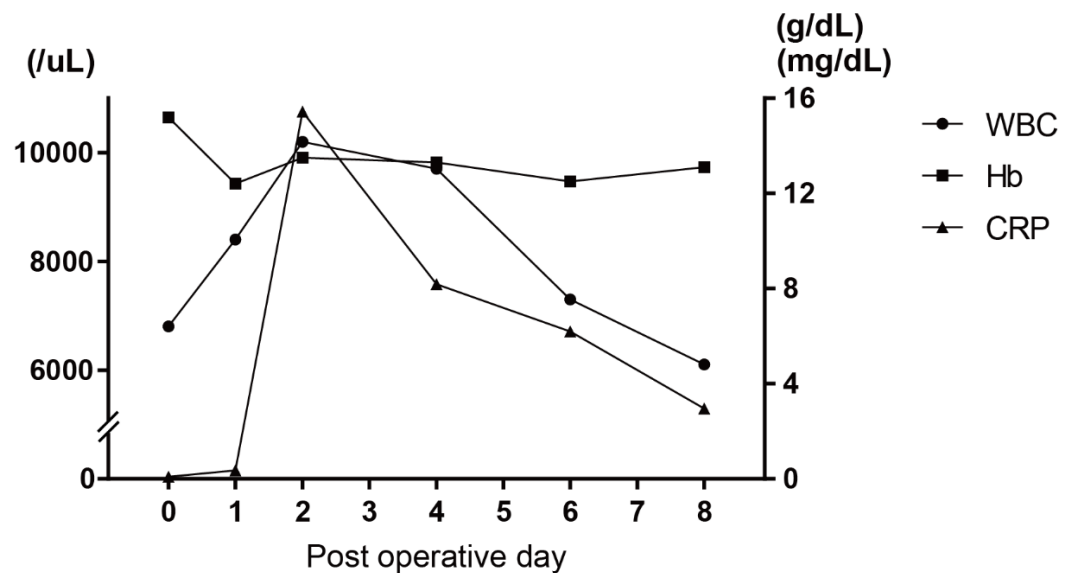


Figure 4. CT angiography (a. Arteries in the neck, b. Arteries and veins in the neck, c. Arteries and veins in the chest to pelvis). No findings suggestive of vasculitis throughout the imaging area and no aneurysms or varicose veins were observed.

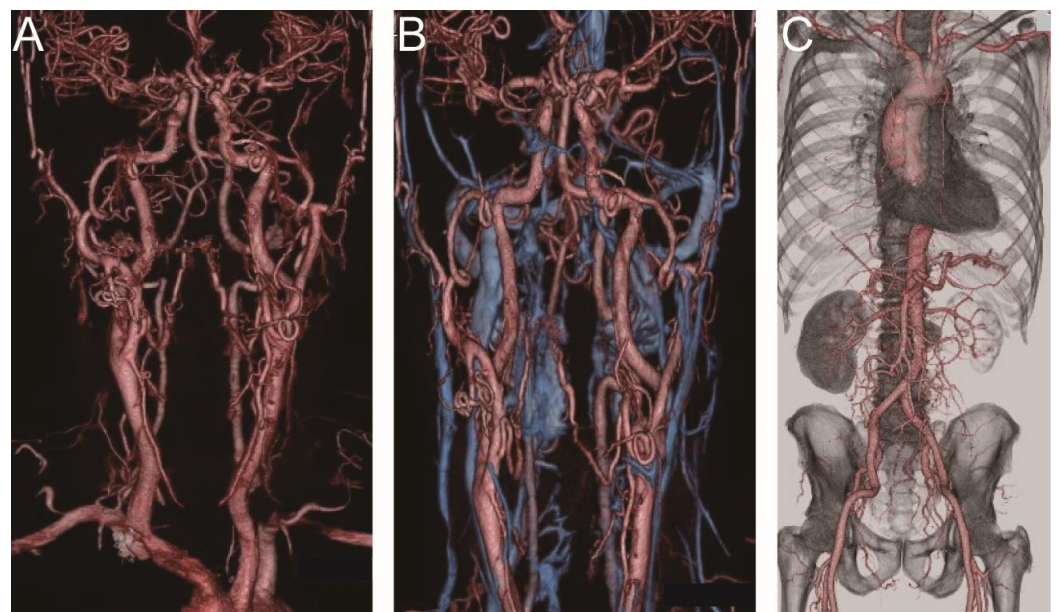


Table 2. Definition of vasculitides adopted by the 2012 Chapel Hill Consensus Conference.

Large-vessel vasculitis Takayasu arteritis Giant cell arteritis	Vasculitis affecting large arteries more often than other vasculitides. Large arteries are the aorta and its major branches. Any size artery may be affected
Medium-vessel vasculitis Polyarteritis nodosa Kawasaki disease	Vasculitis predominantly affecting medium arteries defined as the main visceral arteries and their branches. Any size artery may be affected. Inflammatory aneurysms and stenoses are common
Small-vessel vasculitis	Vasculitis predominantly affecting small vessels, defined as small intraparenchymal arteries, arterioles, capillaries, and venules. Medium arteries and veins may be affected
ANCA-associated vasculitis Microscopic polyangiitis Granulomatosis with polyangiitis Eosinophilic granulomatous with polyangiitis	Necrotizing vasculitis, with few or no immune deposits, predominantly affecting small vessels, associated with MPO-ANCA or PR3-ANCA
Immune complex vasculitis Antiglomerular basement membrane disease Cryoglobulinemic vasculitis IgA vasculitis Hypocomplementemic urticarial vasculitis	Vasculitis with moderate to marked vessel wall deposits of immunoglobulin and/or complement components predominantly affecting small vessels. Glomerulonephritis is frequent
Variable vessel vasculitis Behçet's disease Cogan's syndrome	Vasculitis with no predominant type of vessel involved that can affect vessels of any size and type
Single organ vasculitis Cutaneous leukocytoclastic angiitis Cutaneous arteritis Primary CNS vasculitis Isolated aortitis Others	Vasculitis in arteries or veins of any size in a single organ that has no features that indicate that it is a limited expression of a systemic vasculitis. The involved organ and vessel type should be included in the name. Vasculitis distribution may be unifocal or multifocal within an organ.
Vasculitis associated with systemic disease Lupus vasculitis Rheumatoid vasculitis Sarcoid vasculitis Relapsing polychondritis vasculitis Others	Vasculitis that is associated with and may be secondary to a systemic disease. The name should have a prefix term specifying the systemic disease
Vasculitis associated with probable etiology HCV-associated cryoglobulinemic vasculitis HBV-associated vasculitis Syphilis-associated aortitis Drug-associated immune complex vasculitis	Vasculitis that is associated with a probable specific etiology. The name should have a prefix term specifying the association

Drug-associated ANCA-associated vasculitis

Cancer-associated vasculitis

Others

Legend. Revised from the reference [8]. Anti-neutrophil cytoplasmic antibody; ANCA, Myeloperoxidase; MPO, Proteinase 3; PR3, Hepatitis C virus; HCV, Hepatitis B virus; HBV.

Ehlers-Danlos syndrome is a hereditary connective tissue disorder characterized by skin hyperstretching, joint hypermobility, and tissue fragility, which is divided into 13 categories [8, 9]. The present patient had no symptoms of the major or minor criteria. Although the diagnostic criteria include abnormal type III procollagen production in cultured dermal fibroblasts and mutations in the *COL3A1* gene, he declined to take these tests. Finally, he had no hematologic diseases such as leukemia.

Venous rupture can occur due to physical trauma, such as after CV catheterization or other injuries [10, 11]. Examples of rupture in environments that favor rupture include rupture of the internal jugular vein after neck dissection and rupture of blood vessels due to neck infection [5]. Overall, he had no medical history of disease affecting blood vessels, except for hypertension. Although he had high blood pressure at the time of admission, it was not considered to affect venous pressure. Our findings suggest that the blood vessel at the bleeding point in the left facial vein, which may have been weakened, was ruptured by the increased pressure in the entire neck when he coughed.

4. Conclusion

We reported a case of left neck and oral floor swelling possibly induced by bleeding from the left facial vein caused by coughing. We observed a bubble in the vessel at the anastomoses between the JV and the CFV, along with a perforation in the facial vein branching from the CFV. Subsequently, facial vein ligation was performed to address the hemorrhage. The rupture was considered idiopathic, likely due to coughing, as there were no findings indicative of vasculitis syndrome or hereditary predisposition, nor any symptoms suggesting vascular fragility. To prevent potential complications, such as airway stenosis due to neck swelling and the risk of hemorrhagic shock, it was necessary to promptly perform imaging diagnostics and surgical intervention to achieve hemostasis and remove the hematoma.

Funding: None.

Research Ethics Committee Approval: This study was authorized by the Ethics Committee of Yokosuka Kyosai Hospital (Approval number: 23-57) and was compliant with the ethical guidelines of the Declaration of Helsinki.

Acknowledgments: None.

Conflicts of Interest: None.

Supplementary Materials: None.

References

1. Schappert, S.M. and E.A. Rechtsteiner, Ambulatory medical care utilization estimates for 2006. *Natl Health Stat Report*, 2008;(8):1-29.
2. Tsurumaki, N., M. Suzuki, S. Izumi, and M. Hojo, Rupture of a bronchial artery pseudoaneurysm after radiotherapy. *BMJ Case Rep*, 2024; 17(3).
3. Abreu, A.R., M.A. Campos, and B.P. Krieger, Pulmonary artery rupture induced by a pulmonary artery catheter: a case report and review of the literature. *J Intensive Care Med*, 2004; 19(5):291-6.
4. Li, J., X. Chen, and J. Zhou, Internal carotid artery rupture successfully rescued after resection of locally advanced mucosal malignant melanoma of the eustachian tube: a case report. *J Int Med Res*, 2020; 48(10):300060520963005.
5. Ota, Y., T. Aoki, K. Karakida, and M. Miyasaka, A case of rupture of the internal jugular vein caused by postoperative infection of functional neck dissection. *Tokai J Exp Clin Med*, 2001; 26(4-6):123-5.

6. Kooiman, A.L., J.M. Bakas, J.M.K. van Fessem, W.P.A. Boellaard, S.A.P. Cornelissen, and M.J.E. van Rijn, Spontaneous Iliac Vein Ruptures: A Systematic Review. *Vasc Endovascular Surg*, 2023; 57(6):617-625.
7. Okazaki, T., S. Shinagawa, and H. Mikage, Vasculitis syndrome-diagnosis and therapy. *J Gen Fam Med*, 2017; 18(2):72-78.
8. Bowen, J.M., G.J. Sobey, N.P. Burrows, M. Colombi, M.E. Lavalley, F. Malfait, and C.A. Francomano, Ehlers-Danlos syndrome, classical type. *Am J Med Genet C Semin Med Genet*, 2017; 175(1):27-39.
9. Germain, D.P. and Y. Herrera-Guzman, Vascular Ehlers-Danlos syndrome. *Ann Genet*, 2004; 47(1):1-9.
10. Ono, Y., E. Ueshima, N. Nakanishi, K. Shinohara, I. Yamada, and J. Kotani, Right thyrocervical trunk rupture after right internal jugular vein puncture: a case report and systematic review of the literature. *JA Clin Rep*, 2022; 8(1):74.
11. Luo, Y., H. Yuan, and Z.S. Cao, Residual foreign body in the neck after trauma results in the delayed rupture of the common carotid and internal jugular vein: a case report. *J Med Case Rep*, 2013; 7:13.