

# Xanthogranulomatous Pyelonephritis: An Uncommon form of Pyelonephritis Highlighted in a Case Report

Danielle Malavazi Oliveira <sup>1,\*</sup>, Bárbara Sthefany de Paula Lacerda <sup>1</sup>, Matheus Compart Hemerly <sup>1</sup>, Maria Isabel Lima dos Santos <sup>1</sup>, Weverton Machado Luchi <sup>1</sup>

<sup>1</sup> Hospital Universitário Cassiano Antonio Moraes, Universidade Federal do Espírito Santo (HUCAM-UFES), Espírito Santo, ES, Brazil.

\* Correspondence: dani\_malavazi@hotmail.com.

**Abstract:** Xanthogranulomatous pyelonephritis is a rare and aggressive variant of pyelonephritis, characterized by chronic granulomatous inflammation that progresses to destruction of the renal parenchyma and renal failure. Early diagnosis is a challenge. We present the case of a 7-year-old girl with high fever, associated with low back pain, anorexia and vomiting for 30 days. After antibiotic therapy, radical nephrectomy was required for definitive treatment. Due to its rare and aggressive nature, which often leads to the loss of the affected kidney, it is essential to alert healthcare professionals about the importance of early diagnosis to prevent disease progression and improve the patient's prognosis. We will use a case report to explore the clinical, radiological and pathological aspects related to xanthogranulomatous pyelonephritis.

**Keywords:** Pyelonephritis; Xanthogranulomatous; Urinary Tract Infection.

**Citation:** Oliveira MO, Lacerda BSP, Hemerly MC, Santos MIL, Luchi WM. Xanthogranulomatous Pyelonephritis: An Uncommon form of Pyelonephritis Highlighted in a Case Report. Brazilian Journal of Case Reports. 2025 Jan-Dec;05(1):bjcr4.

<https://doi.org/10.52600/2763-583X.bjcr.2025.5.1.bjcr4>

Received: 17 April 2024

Accepted: 24 June 2024

Published: 27 June 2024



**Copyright:** This work is licensed under a Creative Commons Attribution 4.0 International License (CC BY 4.0).

## 1. Introduction

Xanthogranulomatous pyelonephritis (XGP) is an uncommon form of chronic pyelonephritis characterized by suppurative granulomatous destruction of the renal parenchyma, often associated with urinary tract obstruction [1]. Due to its similarity to kidney neoplasms and other inflammatory processes, both in clinical-radiological characteristics and macroscopic aspects observed during surgery, XGP has been known as "*the great imitator*", thus creating an obstacle for early recognition and treatment. Computed tomography (CT) is the most precise imaging exam used to diagnose XGP, allowing for evaluation of the extent of inflammation and surgical planning [2]. Definitive diagnosis is made through histopathological analysis of the removed kidney tissue. The first line of treatment involves surgery, either partial or radical nephrectomy, after an initial round of antibiotics [3]. We will discuss this topic using a rare pediatric case to illustrate the clinical, radiological, and pathological findings associated with XGP.

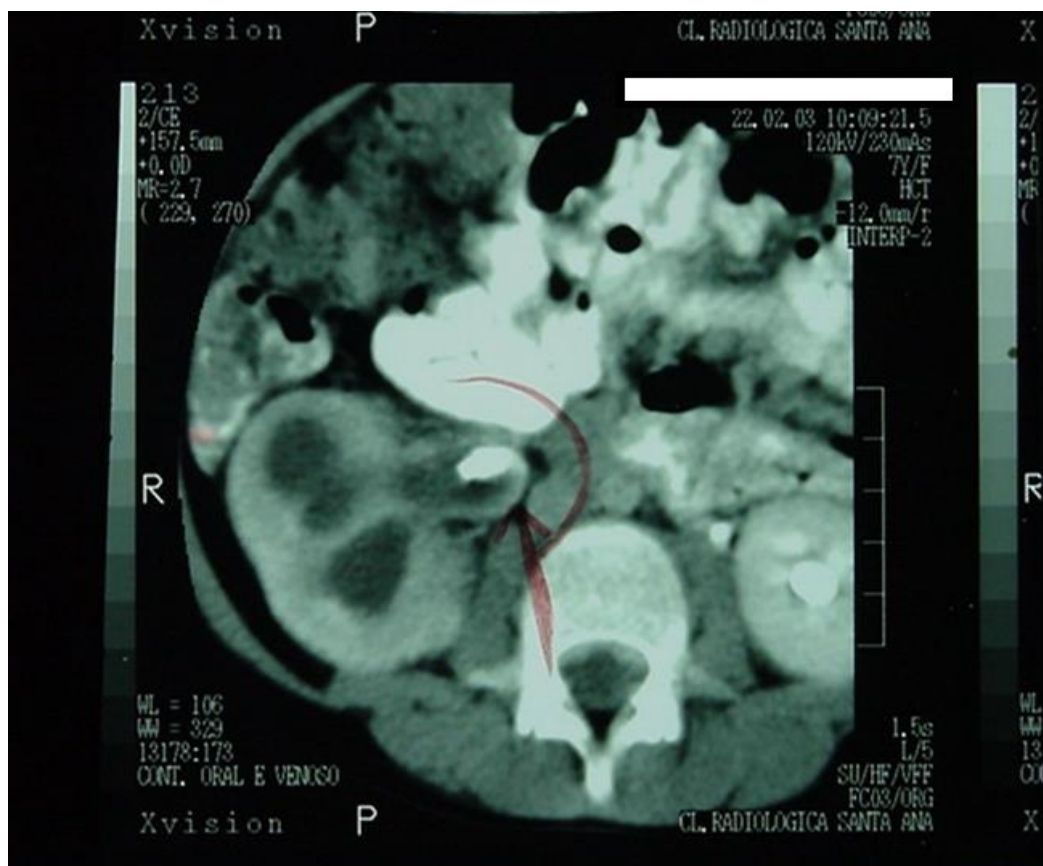## 2. Case Report

A 7-year-old female, weighing 10 kg (p10), height of 115 cm (p10-25), previously healthy, admitted with a history of daily high-grade fever in the past 30 days, associated with abdominal, lumbar and right flank pain, anorexia, and vomiting. Physical examination revealed adynamia, pallor, and pain during deep palpation of the right hypochondriac region. On admission, labs showed a blood urea nitrogen level of 19 mg/dL, creatinine of 0.7 mg/dL, hemoglobin of 9.3 g/dL, leukocytes of 5,700/mm<sup>3</sup>, platelets of 487,000/mm<sup>3</sup>, and erythrocyte sedimentation rate (ESR) of 19 to 102 mm. Urine culture

was positive for non-resistant *Escherichia coli*. The patient was hospitalized and treated for a urinary tract infection (UTI). After 7 days of amikacin followed by 11 days of ceftriaxone, the patient continued to experience a daily fever ranging from 37.9°C to 38.8°C and showed no clinical improvement.

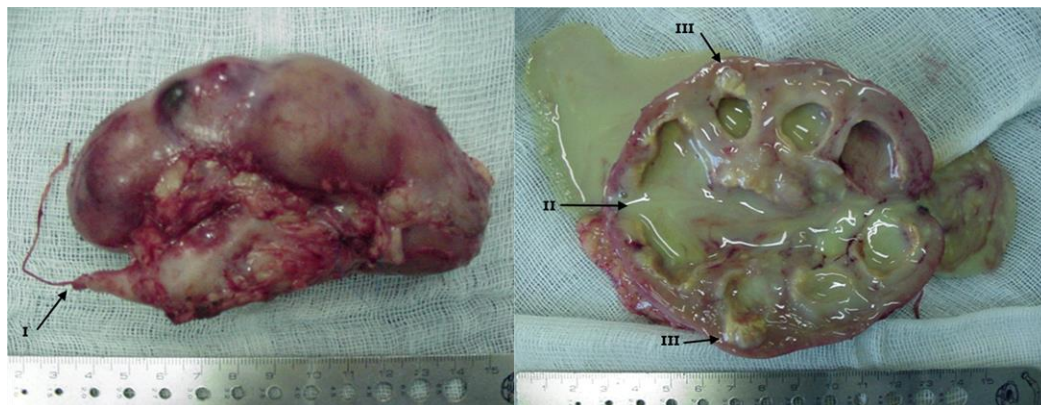
Additional investigation with ultrasonography of the urinary system revealed an enlarged volume of the right kidney (12.2x8.9x5.4cm) with intraparenchymal collections of liquid containing debris. Urine analysis (UA) persisted with pyuria, and bacterioscopy revealed gram-positive cocci in pairs, although all sequential urine cultures were negative. The first blood culture was negative, however, a second test identified *Staphylococcus aureus* susceptible to oxacillin. The patient was started on oxacillin and showed temporary improvement in fever and overall state. After 7 days, both blood and urine cultures were negative, however, the fever returned. A CT scan of the abdomen and pelvis (Figure 1) revealed pyohydronephrosis in the right kidney with a stone at the ureteropelvic junction (UPJ). Excretory urography showed stenosis at the right UPJ due to the stone, and scintigraphy demonstrated a significant functional deficit in the right kidney (4.7%).

**Figure 1.** Abdominal computed tomography. Pyohydronephrosis in the right kidney and stone at the ureteropelvic junction (red arrow).

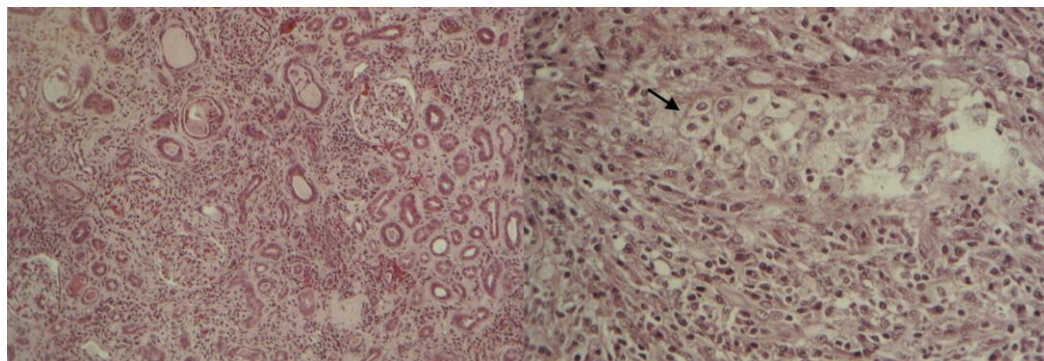


In light of this scenario, surgical intervention was required, and a radical right kidney nephrectomy was performed. Histological analysis confirmed the diagnosis of xanthogranulomatous pyelonephritis (Figures 2 and 3). The patient clinically improved, presented weight gain, and had no new fever episodes after the surgical procedure. She was discharged with an outpatient referral. A review of the diagnostic and treatment process is shown in figure 4.

**Figure 2.** Surgical specimen: Enlarged right kidney, stenosis at the right ureteropelvic junction, and secondary hypoplasia of the right ureter (arrow I). Transverse section of the right kidney shows pyonephrosis (arrow II) and granulomas (arrow III) in the renal parenchyma. Provided by Marco Aurélio Barbieri Ferreira, Pediatric Surgeon.



**Figure 3.** Optical microscopy of surgical specimen: Left - Kidney: Diffuse inflammatory infiltrate with a large number of macrophages, plasma cells, lymphocytes, and giant cells, replacing the renal parenchyma. Right - Mononuclear macrophages filled with fat, known as xanthogranulomatous cells (black arrow). H&E; 400x. (Provided by the HUCAM Pathology Service).



### 3. Discussion

#### 3.1 Overview

XGP is a rare and aggressive type of chronic pyelonephritis, mostly seen in middle-aged women. It may mimic various kidney neoplasms and inflammatory processes, making diagnosis challenging, often leading to discovery during advanced stages of the disease and with extrarenal involvement [4]. The term "xanthogranulomatous" was created in 1944 by Osterlind, however, the first description of this disease was in 1916 by Schlazenhauer. Records also indicate a case of pyelonephritis progressing to a renocolic fistula, a potential complication of XGP, dating back to the 5th century BC by Hippocrates [5]. In 1978, Malek and Elder proposed a 3-stage classification system for XGP: I, affected area restricted to the renal parenchyma; II, involvement of perirenal tissues (adipose tissue); III, involvement of tissues and organs adjacent to the kidney. However, this classification method has limited use in studies, and correlation between disease stage and mortality has not been established [6].

#### 3.2 Clinical Aspects and Symptoms

Characterized by suppurative granulomatous destruction of the renal parenchyma, XGP is generally associated with chronic obstructive uropathy, caused by either structural

changes or staghorn calculi, and recurrent urinary tract infections [1, 7]. As shown in this case report, the patient presented with structural changes, such as stenosis of the ureteropelvic junction and hypoplasia of the right ureter, and calculi, leading to obstructive uropathy.

In pediatrics, XGP most commonly occurs in boys under the age of 8 due to a higher prevalence of structural alterations in the urinary tract, and it has been reported in 2-month-old infants [8]. Studies have accounted for less than 300 cases in the pediatric population and even fewer in female children [9]. Similar to our case, data shows that nearly all patients are symptomatic and often present with multiple symptoms like diffuse abdominal and flank pain, persistent fever, delayed growth, and weight loss. Additionally, approximately half of affected children present with a palpable abdominal mass [10, 11]. In adults, women between the 5th and 6th decades of life are primarily affected and present with urinary complaints such as dysuria, frequent urination, and macroscopic hematuria, as well as the symptoms observed in children [4, 12]. However, due to XGP's broad spectrum of presentations, the limited data available and the lack of studies comparing adult and pediatric cases, the prevalence of specific symptoms throughout different age groups has yet to be fully understood, making it substantially difficult to find key differences when comparing these two groups.

Bacteriuria and pyuria are found in 50 to 70% of cases, with *E. coli* and *Proteus* spp. being the predominant pathogens found in both pediatric and adult populations [7, 11]. However, urine cultures may not be positive due to frequent prior use of antibiotics. A recent meta-analysis that compared 53 studies with a total of 868 patients found that 67% of affected patients were female and 83% of the total patients had obstructive uropathy, most commonly due to calculi. Approximately 26% had negative urine cultures, while 19.6% of positive cultures showed *E. coli*, and 14.3% showed *P. mirabilis* [13]. Laboratory abnormalities include anemia, leukocytosis, and elevated inflammatory markers, like C-reactive protein (CRP) and erythrocyte sedimentation rate (ESR). Hepatic dysfunction may be present in up to 50% of adult patients [6] and records of gastrointestinal symptoms are rare [14].

### 3.3 Risk Factors

Risk factors include congenital defects, structural urinary tract alterations, especially UPJ stenosis and ureteropelvic duplication, as well as diseases such as diabetes mellitus, metabolic syndrome, rheumatoid arthritis, hepatitis C, immunosuppression, obesity, and cirrhosis [8]. The etiopathogenesis of XGP remains uncertain. It is believed that other mechanisms associated with recurrent urinary tract infections, obstructive factors, and kidney stones are involved, given that only a small percentage of patients with these conditions develop XGP. Possible mechanisms include altered immune response, vascular occlusion, local lymphatic dysfunction, and changes in lipid metabolism at renal tissue level [7]. In 2017, Datuna et al. evaluated the expression of vimentin, a protein involved in cholesterol homeostasis, migration, and activation of macrophages during inflammation, in renal tissue. The results demonstrated increased vimentin expression in active areas of the kidney affected by XGP, while it decreased in normal tissue and areas of fibrosis [15].

### 3.4 Pathological Findings

Macroscopically, the affected kidney presents with focal or diffuse enlargement, containing soft yellowish purulent nodules with debris filling the renal calyces and areas of diffuse scarring [16]. Histopathological analysis of lesions reveals the replacement of renal parenchyma with immune cell infiltration, including neutrophils, lymphocytes, plasma cells, fibroblasts, histiocytes, and multinucleated giant cells. These features can be observed in Figures 2 and 3, as chronic inflammation replaced our patient's renal parenchyma with abscess formation. The presence of lipid-laden macrophages, known as

xanthoma cells, is a distinct finding that stains positively for lysozyme, CD68, and vimentin. Granulomas are also present, along with necrosis, fibrosis, and hemorrhage [8, 17]. This process can be focal or diffuse, most commonly with diffuse involvement of the kidney and permanent loss of function. Focal processes represent 20% of cases, restricted to a single renal pole and its cortex, confirmed only by histological analysis of renal parenchyma. Loss of kidney function can be assessed by dynamic renal scintigraphy, as shown in this case report [18].

XGP can potentially invade nearby organs and cause abscess formation in the psoas muscle, diaphragm, large vessels, duodenum, liver, and spleen. The presence of fistulas is another relatively common complication, occurring in up to 8% of patients. A systematic review found nephrocutaneous fistulas to the flank region and nephrocolic fistulas as the most frequent subtypes [6, 19].

### 3.4 Diagnosis & Imaging

A differential diagnosis should be made with renal cell carcinoma, renal cystic diseases, renal abscesses, renal tuberculosis, lymphoma, angioliipoma, malakoplakia, and Wilms' tumor [8]. Given the diversity of possibilities, preoperative assessment can be challenging, with less than half of patients receiving an accurate diagnosis [6]. The definitive diagnosis of XGP is made only by histopathological analysis of tissue obtained from surgical specimens.

As demonstrated in our case, patients who fail to show clinical improvement with antibiotic treatment, need to undergo further evaluation. Ultrasonography is used during the initial assessment of the urinary tract in suspected cases of XGP and can detect increased kidney volume along with multiple fluid collections that appear as anechoic or hypoechoic regions. These findings correspond to either dilated renal calyces or areas of parenchymal destruction, leading to a loss of corticomedullary differentiation [2, 16]. A CT scan is the most accurate exam for diagnosing XGP, used to evaluate the extent of inflammation and plan surgical procedures. CT findings in XGP correspond to diffuse kidney enlargement and areas of hypoattenuation replacing renal parenchyma, indicating dilated calyces or areas of replaced parenchyma with purulent material. This dilation of the calyces associated with a thinned cortex led to the identification of the "bear paw sign," a specific CT finding observed in over 70% of cases in a retrospective study [20]. Our findings collaborate with both ultrasonography and CT scan modifications reported in previous studies, with significant kidney enlargement and changes associated with pyohydro-nephrosis.

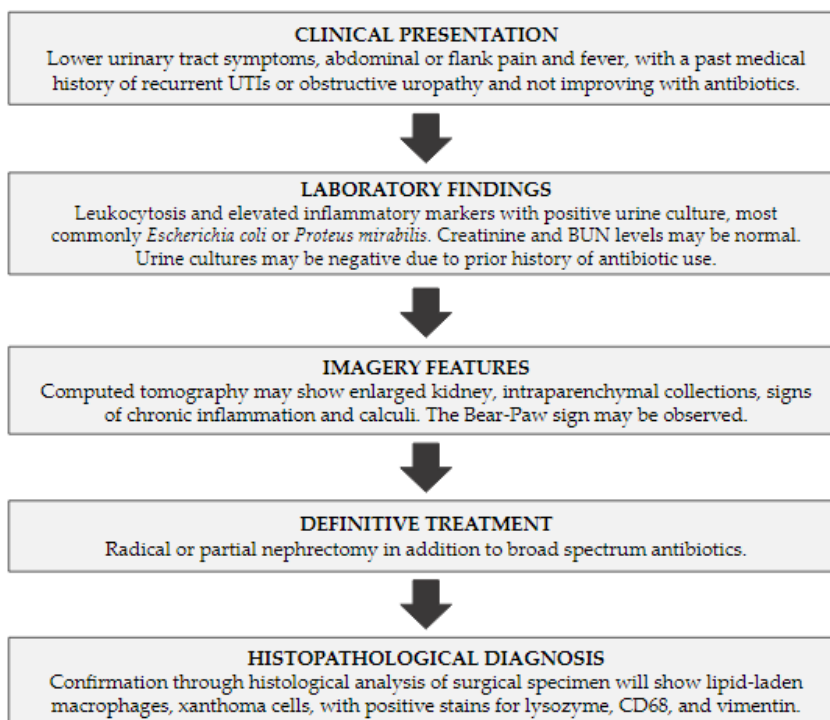
### 3.5 Treatment & Prognosis

The treatment of XGP involves broad-spectrum antibiotic therapy combined with urological surgical intervention. According to a meta-analysis done by Gravestock et al., the most common intravenous antibiotic regimens used are piperacillin-tazobactam, followed by ceftriaxone and aminoglycosides, while ciprofloxacin, nitrofurantoin, and sulfamethoxazole-trimethoprim are the most common oral antibiotics. A surgical approach is optimal and available data shows good prognosis, with lower mortality rates when treated early [13]. Post-operative complications are usually associated with post-operative sepsis [14]. However, further follow-up studies are required to allow for a better, less biased, understanding of the long-term implications of XGP.

In cases with diffuse involvement, radical nephrectomy is recommended, including the removal of affected perirenal tissues and fistulas. A recent study has shown that out of 841 patients with XGP, 99.8% underwent a radical nephrectomy, with 67% requiring an open surgery approach [13]. Studies have shown that focal presentations may be managed with partial nephrectomy, resulting in a good response and rare recurrence [21]. Partial nephrectomies should be considered in pediatric cases if affected kidney shows signs of viability with some preserved nephron function [22]. There have been reported cases

where focal XGP treatment involved only antibiotics (methacycline, cefazolin combined with cephalexin) and radiological monitoring with CT. Although there is no consensus regarding the effectiveness of this approach, it may be appropriate in patients who are unable to undergo surgery [23, 24]. To the best of our knowledge, there are no reported cases of disease recurrence on the contralateral kidney [8].

**Figure 4.** Diagnostic Steps to XGP.



#### 4. Conclusion

Xanthogranulomatous pyelonephritis is a rare and aggressive disease associated with high morbidity and mortality rates if not diagnosed and treated early. Although less frequent in pediatric patients, this diagnosis needs to be postulated in children who present with palpable renal mass, intraabdominal abscesses, or loss of renal function, with or without the presence of nephrolithiasis. Due to XGP's ability to mimic a variety of pathologies, including neoplasms, diagnosis has become particularly difficult. Current data suggests that CT imaging is the best exam during initial investigation and broad-spectrum antibiotics combined with nephrectomy as the most appropriate treatment regimen. Further studies are necessary to elucidate other treatment options and better protocols when treating patients with XGP, such as antibiotic choice and duration, surgical approaches, and post-operative care. Our findings aim to inform health professionals about the variety of clinical presentations involving XGP and raise awareness of the importance of early diagnosis when treating patients with this disease.

**Funding:** None.

**Research Ethics Committee Approval:** We declare that the patient approved the study by signing an informed consent form and the study followed the ethical guidelines established by the Declaration of Helsinki.

**Acknowledgments:** None.

**Conflicts of Interest:** None.

**Supplementary Materials:** None.

## References

1. Mittal BV, Badhe BP. Xanthogranulomatous pyelonephritis (a clinicopathological study of 15 cases). *J Postgrad Med*. 1989 Oct;35(4):209-14. Erratum in: *J Postgrad Med* 1990 Apr;36(2):103. PMID: 2490367.
2. Hayes WS, Hartman DS, Sesterbenn IA. From the Archives of the AFIP. Xanthogranulomatous pyelonephritis. *Radiographics*. 1991 May;11(3):485-98. doi: 10.1148/radiographics.11.3.1852939. PMID: 1852939.
3. Zorzos I, Moutzouris V, Korakianitis G, Katsou G. Analysis of 39 cases of xanthogranulomatous pyelonephritis with emphasis on CT findings. *Scand J Urol Nephrol*. 2003;37(4):342-7. doi: 10.1080/00365590310004752. PMID: 12944195.
4. Jha SK, Aeddula NR. Xanthogranulomatous Pyelonephritis. 2024.
5. Osterlind S. Uber pyelonephritis xanthomatosa. *Acta Chir Scand*. 1944;369-76.
6. Harley F, Wei G, O'Callaghan M, Wong LM, Hennessey D, Kinnear N. Xanthogranulomatous pyelonephritis: a systematic review of treatment and mortality in more than 1000 cases. *BJU Int*. 2023 Apr;131(4):395-407. doi: 10.1111/bju.15878. Epub 2022 Sep 26. PMID: 35993745.
7. Jang TL, McKoy T, Hakim J, Polenakovik HM. Xanthogranulomatous pyelonephritis - A diagnostic and therapeutic dilemma. *Am J Med Sci*. 2023 Mar;365(3):294-301. doi: 10.1016/j.amjms.2022.11.004. Epub 2022 Dec 5. PMID: 36473546.
8. Sayed AG, Badghaish T, Abdo N, Nasir A. Diffuse Xanthogranulomatous pyelonephritis: A Rare Disease With A Common Presentation. *Cureus*. 2023 Aug 25;15(8):e44118. doi: 10.7759/cureus.44118. PMID: 37750147; PMCID: PMC10518206.
9. Deng QF, Chu H, Peng B, Liu X, Cao YS. Case report: Localized xanthogranulomatous pyelonephritis in children: A case report and literature review. *Front Pediatr*. 2022 Jul 18;10. Available from: <https://www.frontiersin.org/articles/10.3389/fped.2022.952989/full>
10. Malek RS, Elder JS. Xanthogranulomatous pyelonephritis: a critical analysis of 26 cases and of the literature. *J Urol*. 1978 May;119(5):589-93. doi: 10.1016/s0022-5347(17)57559-x. PMID: 660725.
11. Møller JC, Kristensen IB. Xanthogranulomatous pyelonephritis. A clinico-pathological study with special reference to pathogenesis. *Acta Pathol Microbiol Scand A*. 1980 Mar;88(2):89-96. PMID: 7368938.
12. Bkiri S, Abbad F, Ghadouane M. Xanthogranulomatous Pyelonephritis With Extension to the Liver: A Case Report. *Cureus*. 2023 Aug 4;15(8):e42929. doi: 10.7759/cureus.42929. PMID: 37667725; PMCID: PMC10475155.
13. Gravestock P, Moore L, Harding C, Veeratterapillay R. Xanthogranulomatous pyelonephritis: a review and meta-analysis with a focus on management. Vol. 54, *International Urology and Nephrology*. Springer Science and Business Media B.V.; 2022. p. 2445-56. <https://doi.org/10.1007/s11255-022-03253-x>.
14. Li L, Parwani A V. Xanthogranulomatous Pyelonephritis. Vol. 135, *Arch Pathol Lab Med*. 2011. p. 671-4.
15. Ostalska-Nowicka D, Mackowiak-Lewandowicz K, Konwerska A, Zachwieja J. Early Progression of Xanthogranulomatous Pyelonephritis in Children Might Be Dependent on Vimentin Expression. *Am J Case Rep*. 2017 Oct 5;18:1066-1072. doi: 10.12659/ajcr.904376. PMID: 28978905; PMCID: PMC5637626.
16. Korkes F, Favoretto RL, Bróglia M, Silva CA, Castro MG, Perez MD. Xanthogranulomatous pyelonephritis: clinical experience with 41 cases. *Urology*. 2008 Feb;71(2):178-80. doi: 10.1016/j.urology.2007.09.026. PMID: 18308077.
17. Bourm KS, Menias CO, Ali K, Alhalabi K, Elsayes KM. Spectrum of Xanthogranulomatous Processes in the Abdomen and Pelvis: A Pictorial Review of Infectious, Inflammatory, and Proliferative Responses. *AJR Am J Roentgenol*. 2017 Mar;208(3):475-484. doi: 10.2214/AJR.16.17075. Epub 2017 Jan 17. PMID: 28095017.
18. Kelly C, Anderson S, Looney A, Shannon N, Senaratne R, O'Connor E, Breen K, Lennon G, McGuire B, Murphy M, Moran D, Galvin D. Nephrectomy for xanthogranulomatous pyelonephritis-a not-so-simple solution. *Ir J Med Sci*. 2023 Aug 23. doi: 10.1007/s11845-023-03496-2. Epub ahead of print. PMID: 37610600.
19. Anand S, Tomar S, Jain V, Barwad A, Kandasamy D. Xanthogranulomatous pyelonephritis with nephrocutaneous fistula. *J Pediatr Surg Case Rep*. 2021 Jan;64:101674. doi: 10.1016/j.epsc.2020.101674.
20. Tamburrini S, Comune R, Lassandro G, Pezzullo F, Liguori C, Fiorini V, Picchi SG, Lugarà M, Del Biondo D, Masala S, Tamburro F, Scaglione M. MDCT Diagnosis and Staging of Xanthogranulomatous Pyelonephritis. *Diagnostics (Basel)*. 2023 Apr 4;13(7):1340. doi: 10.3390/diagnostics13071340.
21. Al-Ghazo MA, Ghalayini IF, Matalka II, Al-Kaisi NS, Khader YS. Xanthogranulomatous pyelonephritis: Analysis of 18 cases. *Asian J Surg*. 2006 Oct;29(4):257-61. doi: 10.1016/S1015-9584(09)60099-3. PMID: 17098659.
22. Alenazi KA. Atypical Clinical Presentation of Xanthogranulomatous Pyelonephritis in a Female Child: A Case Report. *Cureus*. 2024 Feb 6; DOI: 10.7759/cureus.53666.
23. Chuang CK, Lai MK, Chang PL, Huang MH, Chu SH, Wu CJ, Wu HR. Xanthogranulomatous pyelonephritis: experience in 36 cases. *J Urol*. 1992 Feb;147(2):333-6. doi: 10.1016/s0022-5347(17)37229-4. PMID: 1732587.
24. Raziell A, Steinberg R, Kornreich L, Mor C, Golinsky D, Ziv N, Freud E, Zer M. Xanthogranulomatous pyelonephritis mimicking malignant disease: is preservation of the kidney possible? *Pediatr Surg Int*. 1997 Sep;12(7):535-7. doi: 10.1007/BF01258721. PMID: 9238126.